

ANALGESIA FOR RETROBULBAR BLOCK

- Comparison of Remifentanyl, Alfentanil and Fentanyl -

BEHZAD MAGHSOUDI^{*}, MOHAMMAD REZ TALEBNEJAD^{**}
AND ESFANDYAR ASADIPOUR^{***}

Abstract

Background: The injection of retrobulbar block is associated with significant pain and discomfort. Therefore a short-acting IV analgesic before retrobulbar injection has been advocated.

Objective: To compare remifentanyl, alfentanil and fentanyl in providing analgesia for retrobulbar block injection.

Methods: 69 patients were enrolled randomly into three groups of 23 each to receive either Remifentanyl 1 µg/kg, Alfentanil 20 µg/kg or Fentanyl 2 µg/kg as an IV bolus dose prior to retrobulbar injection. Mean arterial pressure (MAP) and heart rate (HR) were recorded and Numerical Pain Score (NPS) were assessed by a blinded observer.

Results: Remifentanyl prevented increase in MAP and HR while alfentanil and fentanyl were ineffective in this purpose ($p < 0.05$). NPS was significantly lower in remifentanyl group ($p < 0.05$).

Conclusion: Remifentanyl 1 µg/kg prior to retrobulbar injection

From Shiraz Univ. of Medical Sciences, Shiraz, Iran.

* Associate Professor, Department of Anesthesiology.

** Assistant Professor, Department of Ophthalmology.

*** MD.

Correspondence: B. Maghsoudi, Department of Anesthesiology, Faghihi Hospital, Zand St., Shiraz, Iran. P.O. Box: 71345-1343, Tel: +98 9171119264, Fax: +98 711 2307072, E-mail: maghsodb@sums.ac.ir.

provide excellent hemodynamic stability and ensure analgesia.

Keywords: Analgesia: Eye surgery; Anesthesia, Regional: Retrobulbar block; Remifentanyl; Alfentanil; Fentanyl.

Introduction

General anesthesia is hazardous in a large number of patients undergoing ophthalmic surgery, as many of them are elderly with multisystem diseases¹. Likewise many ophthalmic procedures can be performed safely in an outpatient setting, using local (peri-retrobulbar block, PRBB) or topical anesthesia. However, insertion of the needle is associated with pain and anxiety which can produce hemodynamic instability and thus more discomfort². As the patient must be calm, cooperative and aware during the block, some kind of short-acting premedication can be helpful³.

The ideal premedication should ensure analgesia, decrease discomfort, limit patient's movement and produce no cardiovascular or respiratory side effects³. However, the use of sedative or anxiolytic drugs has been criticized in this setting particularly in elderly patients as they can compromise the patient's consciousness and cooperation^{4,5}.

Many agents and combinations have been used for this purpose including remifentanyl, alfentanil, fentanyl, propofol and midazolam³, but no comparison studies were made between the three narcotics.

Our study compared the effectiveness of remifentanyl, alfentanil and fentanyl in providing analgesia for RBB injection and also assessed whether these drugs could provide hemodynamic stability.

Methods and Materials

Following the Institutional Ethic Committee approval, written informed patient consent was obtained. A prospective clinical trial of 69 patients (aged 50-70, ASA I-II) to undergo intraocular surgery under retrobulbar blocks was undertaken. An $\alpha = 0.01$ and $1 - \beta = 90\%$ was used

to determine the sample size of 23 in each group. Patients with hypertension, hyperthyroidism, frequent cough, neurologic or psychiatric disorders, contraindication to any of the study drugs and visual impairment of the nonoperative eyes, were excluded.

The procedure was carefully explained to each patient: the block, the analgesic and Numerical Pain Score (NPS).

In the operating room standard monitoring was instituted (Poyandegan Raha Saadat, Tehran, Iran) and supplemental O₂ was administered at 2^{L.min⁻¹} by nasal cannula. A 20 gauge IV cannula was inserted and attached to an infusion of normal saline. No oral premedication was given.

Patients were then randomly assigned by a computer generated random number table to three groups of 23 each. In group F an IV bolus of 2 µg/kg fentanyl (Janssen-Cilag, Belgium) was slowly administered 4 minutes before block injection. In group A and group R, 90 seconds before RBB placement, alfentanil 20 µg/kg (Janssen-Cilag, Belgium) and remifentanil 1 µg/kg (Glaxosmithkline, UK) were administered respectively. All the blocks were performed by an attending ophthalmologist using a 1.5 inch 23-gauge needle.

Mean arterial blood pressure (MAP) and heart rate (HR) were recorded just before RBB injection (as baseline value) and at 1, 3 and 5 minutes after block placement. A blinded observer assessed NPS using a 10-point scale⁶. If the respiratory rate decreased to less than 10 breath/minute, the patients were stimulated verbally to breath. Any derangement in the above protocol put the patient out of the study.

Demographic data were compared using One-Way ANOVA for age and weight and chi-square test for sex. Multiple comparisons of the hemodynamic parameters were done using One-Way ANOVA. Statistical comparisons of NPS values were made by using One-Way ANOVA and Fisher exact test. A P-value less than 0.05 were considered statistically significant.

Results

There were no differences in demographic data's among the A, F & R groups (Table 1).

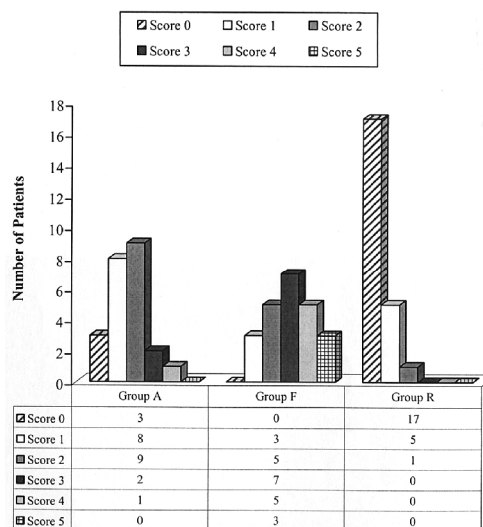
Table 1
Patients' demographics data

Groups	Age (yrs)	Weight (kg)	Male (n)	Female (n)
Group A	68.173 ± 4.49	61.304 ± 9.47	10	13
Group F	66.695 ± 5.57	60.217 ± 7.69	10	13
Group R	65.956 ± 6.45	64.173 ± 11.46	9	14

Note: Age and weight values are Mean ± SD.

Pain associated with the RBB injection was significantly lower in group R as compared with the two other groups ($p < 0.05$). The Numerical Pain Score (NPS) was 0.34 ± 0.71 in group R, while a value of 1.56 ± 0.99 and 2.90 ± 1.19 were recorded for group A and F respectively. A NPS > 5 did not occur in any patients (Fig. 1).

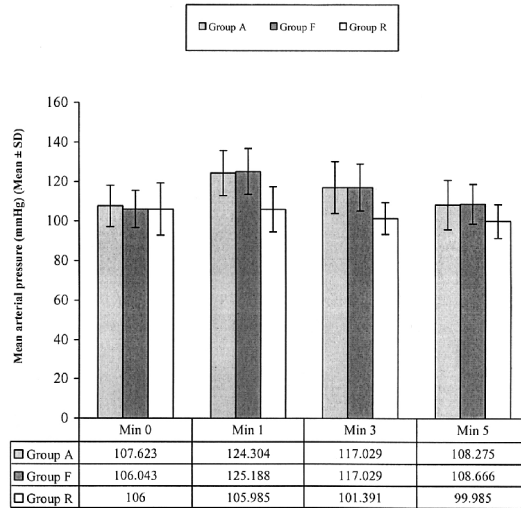
Fig. 1
Numerical pain score (0-10)
for retrobulbar block
injection in the studied groups
($P < 0.05$).



MAP increased significantly over baseline value in group F and A at 1 and 3 minutes after RBB injection, but returned to near baseline at 5th minute. In group R, however, MAP was nearly stable with a nonsignificant decrease over the study. Overall there was significant

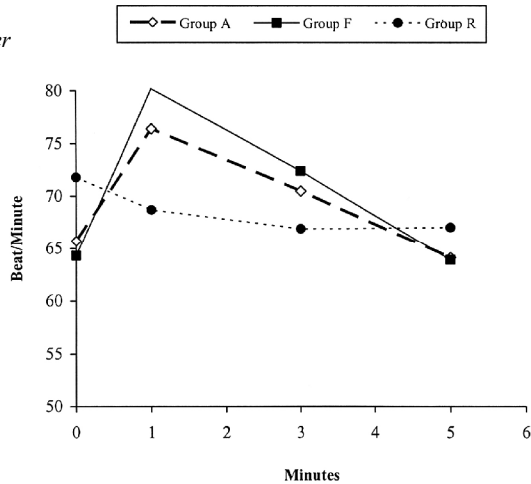
difference in MAP on comparing group R with groups F and A ($P < 0.05$) after RBB injection (Fig. 2).

Fig. 2
Mean arterial pressure before retrobulbar block & at 1, 3, and 5 minutes thereafter.



The HR (Fig. 3), showed a nonsignificant decrease in group R over the measurement period. In contrast, HR demonstrated a significant increase over baseline at 1st minute, returned to near normal at 3rd minute and decreased to a value less than normal at 5th minute in groups F and A. The change in HR was significantly different at all measurements comparing group R with groups F and A ($P < 0.05$).

Fig. 3
Changes in mean heart rate over time in the studied groups



SpO₂ was above 90% in all cases as patients were conscious and responded to verbal stimulation for breathing.

Discussion

Retrobulbar injection is painful and patients often express anxiety over the procedure. Pain and anxiety are associated with systemic problems such as tachycardia, hypertension and dysrhythmia and can make the patient move their eyes thus increasing the risk of complications^{7,8}.

In an attempt to prevent complications, patient can be sedated before the block is administered. However, sedated patients may become uncooperative and feel pain that makes them move². The optimal requirements are therefore a patient who is hemodynamically stable without respiratory depression, who is not anxious and moving during RBB injection and yet who is able to respond to commands⁹.

In this regards opioid drugs can be used for both sedation and analgesia, as a good preemptive analgesia can also provide hemodynamic stability and reduction of IOP^{2,10,11}.

In our study remifentanil, alfentanil and fentanyl were compared as analgesics prior to RBB placement. These short acting narcotics have been used previously as a sole agent or in combination with propofol or midazolam for providing optimal peri-retrobulbar block condition.

A single bolus of 2 µg/kg fentanyl had been used to prevent painful stimulation during block injection and to provide a cooperative and comfortable state².

Alfentanil as used by McHardy et al.¹² and Yee et al¹³, showed beneficial effects in limiting movement during RBB injection and minimized hemodynamic response. Also, Remifentanil an anilopiperidine first approved for clinical use in 1996, provide excellent analgesia during retrobulbar placement^{14,15}.

In our study in comparing these three narcotics, remifentanyl provided superior analgesia for the block injection. The inability of remifentanyl in providing satisfactory condition in the study performed by Boezaart et al is probably due to the low dose (0.3 µg/kg) used⁹.

More hemodynamic stability was found with the use of remifentanyl. The mild decrease in HR and MAP in group R could be attributed to the deep analgesic effect that remifentanyl provided for performing RBB injection and the continuation of depressant cardiovascular effect of this drug after block injection. Both fentanyl and alfentanil were unable to prevent the hemodynamic effects, especially at 1st minute after RBB injection.

As these three narcotics are short-acting and all the patients were cooperative and alert during the performance of the block, the problem of respiratory depression, if any, was solved by verbally stimulating patients to breath.

In conclusion, we recommend the usage of remifentanyl 1 µg/kg 1 minute before RBB injection to ensure analgesia and hemodynamic stability.

Acknowledgement

We gratefully acknowledge the cooperation of our patients who manifested patience and understanding during the performance of this study.

References

1. BARKER JP, ROBINSON PN, VAFIDIS GC, HART GR, ET AL: Local analgesia prevents the cortisol and glycemc response to cataract surgery. *Br J Anesth*; 64:442-5, 1990.
2. INAN UU, SIVAC RG, ERMIS SS AND OZTURK F: Effects of fentanyl on pain and hemodynamic response after retrobulbar block in patients having phacoemulsification. *J Cataract Refract Surg*; 29(6):1137-42, 2003.
3. DONLON JV JR, DOYLE DJ AND FELDMAN MA: Anesthesia for eye, ear, nose and throat surgery, *Miller's Anesthesia Miller*; Ch. 65, Churchill Livingstone Inc., Philadelphia 2005.
4. BOEZAART AP, BERRY RA, LAUDSCHER JJ AND NELL ML: Evaluation of anxiolysis and pain associated with combined peri and retrobulbar eye block for cataract surgery. *J Clin Anesth*; 10:204-10, 1998.
5. SALMON JF, METS B, JAMES MF AND MURRAY AD: Intravenous sedation for ocular surgery under local anesthesia. *Br J Ophthalmol*; 76:598-601, 1992.
6. KALLIO H, UUSITALO RJ AND MAUNUKSELA EL: Topical anesthesia with or without propofol sedation versus retrobulbar/peribulbar anesthesia for cataract extraction; prospective randomized trial. *J Cataract Refract Surg*; 27:1372-79, 2001.
7. FOGGITT PS: Anxiety in cataract surgery: pilot study. *J Cataract Refract Surg*; 27:1651-5, 2001.
8. KIEFER RT, WEINDLER J AND RUPRECHT KW: The endocrine stress response after oral premedication with low-dose midazolam for intraocular surgery in retrobulbar anaesthesia. *Eur J Ophthalmol*; 8:239-45, 1998.
9. BOEZAART AP, BERRY RA, NELL ML AND VAN DYK AL: A comparison of propofol and remifentanyl for sedation and limitation of movement during periretrobulbar block. *J Clin Anesth*; 13(6):422-6, 2001.
10. VIRKKILA ME, ALI-MELKKILA TM AND KANTO JH: Premedication for outpatient cataract surgery: a comparative study of intramuscular alfentanil, midazolam and placebo. *Acta Anaesthesiol Scand*; 36:559-563, 1992.
11. JUENHOFEL S, FEISEL C, SCHMITT HJ AND BIEDLER A: TIVA mit propofol/remifentanyl oder balancierte anesthesia mit sevoflurane/fentanyl bei laparoskopischen operationen. Hamodynamick, Aufwachrherhalten und Nebenwirkungen. *Anaesthesist*; 48:807-12, 1999.
12. MCHARDY FE, FORTIER J, CHANGE F, KRISHNATHAS A AND MARSHALL SI: A comparison of midazolam, alfentanil and propofol for sedationin outpatient intraocular surgery. *Can J Anesth*; 47:211-4, 2000.
13. YEE JB, SCHAFER PG, CRANDALL AS AND PACE NL: Comparison of methohexital and alfentanil on movement during placement of retrobulbar nerve block. *Anesth Analg*; 79(2):320-3, Aug, 1994.
14. REWARI V, MADEN R, KAUL HL AND KUMAR L: Remifentanyl and propofol sedation for retrobulbar nerve block. *Anaesth Intensive Care*; 30(4):433-7, 2002.
15. LEIDINGER W, SCHWINN P, HOFMANN HM AND MEIERHOFER JN: Remifentanyl for analgesia during retrobulbar nerve block placement. *Eur J Anaesthesiol*; 22(1):40-3, 2005.