

INTERVERTEBRAL DISC A SOURCE OF PAIN?  
- LOW BACK PAIN: PROBLEMS AND FUTURE  
DIRECTIONS -

- Case reports -

KALID MALIK\* AND NINOS J JOSEPH\*\*

**Abstract**

**Objective:** The objective of this article is to provide evidence supporting the idea that intervertebral disc is a source of low back pain.

**Summary of Background Data:** Diagnostic tests currently available for diagnosis of a painful disc are inadequate. Treatment protocols for low back pain generally ignore the presence of a painful disc. Pathological processes that may be responsible for discogenic pain are incompletely understood. Without diagnosis and treatment, disc disruption evolves to advanced stages of spinal dysfunction. New treatment modalities are becoming available which if applied early may stop disc disruption.

**Case Reports:** We describe here two case reports where discogenic nature of patients' symptoms was suspected based on patients' history, MRI findings and discography. We highlight the inadequacies of spinal

---

From the Department of Anesthesiology, Illinois Masonic Medical Center, Chicago, IL 60657 USA.

\* Attending Anesthesiologist, Advocate Illinois Masonic Medical Center, Chicago, IL.

\*\* Research Associate, Department of Anesthesiology, Advocate Illinois Masonic Medical Center, Chicago, IL.

Correspondence and reprint requests to Khalid Malik, MD, Department of Anesthesiology, Advocate Illinois Masonic Medical Center, 836W. Wellington Avenue, Chicago, IL 60657, 773-296-5619 (Voice), Fax: 773-296-5362. E-mail: kmalikmd@aol.com.

imaging and discography in detecting a painful disc. A treatment (Intradiscal electrothermal therapy) was then directed exclusively to the intervertebral discs. We provide arguments that link discal therapy to resolution of patients' symptoms. Resolution of patients' symptoms after the discal treatment raised our suspicion that pain emanated from the intervertebral discs.

**Conclusions:** Intervertebral disc is a source of low back pain that is often ignored. No diagnostic test currently exists that can reliably confirm presence of a painful disc. Early diagnosis and treatment of a painful disc may reduce enormous pain and suffering from low back pain.

### **Introduction – High Lights**

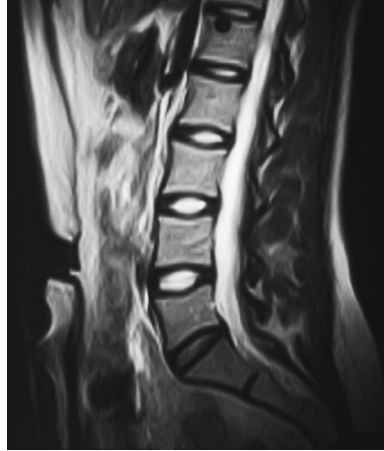- Lumbar intervertebral disc as a source of pain is a controversial subject.
- Diagnostic tests currently available to diagnose a painful disc are inadequate and subjective in nature.
- Current treatment strategies for low back pain often ignore this diagnosis.
- Pathological processes responsible for discal pain are poorly understood.
- A painful disc may often be a source of chronic pain in patients with low back pain.
- Untreated disc disruption may continue to progress to advanced stages of spinal dysfunction causing further morbidity.
- We present two case reports where a treatment was directed exclusively at the intervertebral discs (Intra-Discal Electrothermal Therapy).
- We provide arguments linking discal treatments and resolution of patients' pain.

- These case reports strongly support intervertebral discs as a source of patients' low back pain.
- We discuss possible mechanisms by which a disc can generate pain.
- We make recommendations for early detection and diagnosis of a painful disc.
- With the advent of new treatment modalities, that may arrest discal disruption, early diagnosis of a painful disc is crucial.
- This approach may reduce enormous pain and suffering from low back pain.

### Case 1

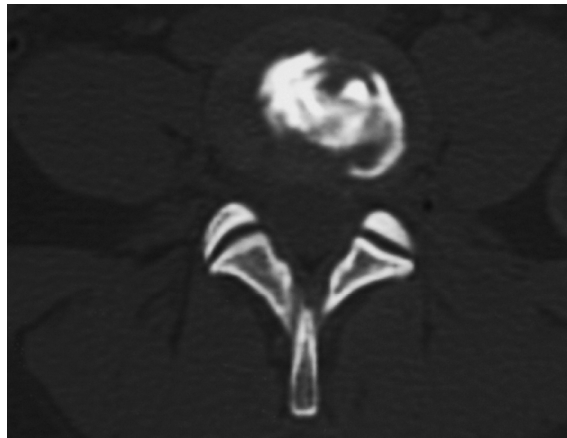
A 28-year-old female, ice skating instructor, is otherwise healthy, not obese (body mass index = 22.6 kg/m<sup>2</sup>) and takes no routine medications. She presented with a one-month history of low back pain unrelated to an identifiable traumatic event. Her pain was primarily located in the low back and did not radiate to her lower extremities. It was typically worse with prolonged sitting and standing. On examination the positive findings were tenderness in the midline over the lower lumbar spinous processes and severe restriction of range of motion of the lower back in all directions. Of note there was complete absence of radicular symptoms and signs and a normal straight leg raise test on both sides. The only abnormality discernable on magnetic resonance imaging (MRI) of the lumbar spine was a loss of T-2 signal at lumbar disc L5-S1 (Fig. 1). Her pain was rated as 9/10 on numeric rating scale (NRS) and she was disabled to a degree where she could no longer perform her regular work and required narcotic analgesics (total daily dose = 32.5 mg parenteral morphine equivalents) and non-steroidal anti-inflammatory drugs (NSAIDs) to control her pain.

*Fig. 1*  
*Sagittal MRI T2 image of lumbar spine (Case 1) showing diminished signal intensity at L5-S1 disc*

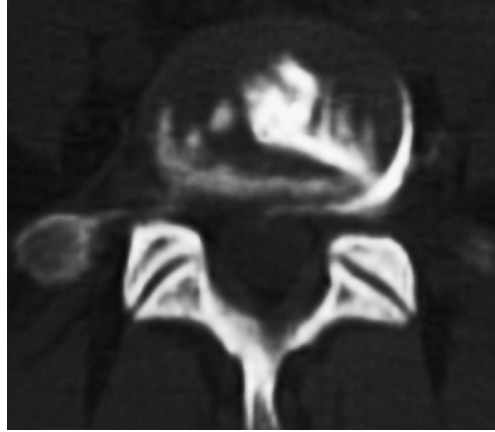


Three fluoroscopically-directed lumbar epidural steroid injections were performed at one-month intervals and she underwent physical therapy at the same time. Four months after the start of her initial pain, lumbar discography was performed at L5-S1 level; the L4-L5 disc was used as a control. On discography patient reported no pain on injection at L4-L5 level but complained of severe concordant pain when the L5-S1 disc was injected. Post-discography computed tomogram (CT) showed a partial annular tear (Grade 2-3, Dallas classification)<sup>4</sup> at L4-L5 level (Fig. 2), but at L5-S1 level there was a complete annular tear (Grade-4) with sub-ligamentous extravasation of dye (Fig. 3).

*Fig. 2*  
*Post-discography CT scan (Case 1) at L4-L5 level showing a Grade 2-3 annular tear*



*Fig. 3*  
*Post-discography CT scan*  
*(Case 1) at L5-S1 level*  
*showing complete (Grade 4)*  
*annular tear with sub-*  
*ligamentous dye extravasation*



Six months after the start of her symptoms Intra-Discal Electro-thermal Therapy (IDET) was performed at the L5-S1 level. Two heating coils were used, one on each side and both coils were heated for 16 minutes at 90°C. After the procedure patient wore lumbar brace for eight weeks and underwent physical therapy for four months. The patient remained off work and continued to require narcotic analgesics (total daily dose = 22.5 mg parenteral morphine equivalents) at six weeks after the procedure. However at twelve weeks, she reported no pain (NRS 0/10), she was off all medications (NSAIDs and narcotic analgesics), she was skating, and was back to her normal work.

## **Case 2**

Patient was a 25-year-old waitress, who presented with pain in her low back for three weeks. The pain radiated down her buttocks and down her right leg to the knee. Her pain was worse with sitting, walking and coughing. She related this pain to a fall that she sustained at work and she had been off work since. She was otherwise healthy and had no history of drug or substance abuse. She was being treated with NSAIDs, narcotic analgesics (total daily dose = 12.4 mg parenteral morphine equivalents) and muscle relaxants. Examination of her lower back revealed limitation of range of motion in all

directions and diffuse tenderness of the lower back. Lumbar spine MRI done at that time showed, disc desiccation at L2-3, L3-4, L4-5 and L5-S1 levels and disc protrusions at L4-5 and L5-S1.

A diagnosis of lumbar radiculopathy was made and she received three interlaminar lumbar epidural steroid injections over the next three months. She continued to use NSAIDs and narcotic analgesics (total daily dose = 22.5 mg parenteral morphine equivalents) during that time. At the end of this treatment she remained in severe pain, however her pain now was localized to her low back and did not radiate to her right leg. The range of motion of her low back remained limited and painful. For the next sixteen months she received several courses of physical therapy and continued her NSAIDs and narcotic analgesics (total daily dose = 15 mg parenteral morphine equivalents). The intensity of her pain remained unchanged (9/10 NRS) and she remained off work. A second MRI was done at this time, which showed no change in disc desiccation at the aforementioned levels, however the size of disc protrusions at L4-5 and L5-S1 had decreased.

Twenty month after her symptoms started, lumbar discography was performed at L2-3, L3-4, L4-5 and L5-S1 levels with L1-2 as a control level. She experienced severe concordant pain at all levels except at L1-2 where pain was discordant. Post-discography CT showed full thickness annular tears (Grades 4 & 5) at all levels except at L1-2 where the tear was limited to the inner annulus (Grade 2-3). Diagnosis of annular disc tears and discogenic pain was made at L2 through S1 levels. Twenty-two months after the start of initial pain, IDET was performed at L2-3, L3-4, L4-5 and L5-S1 levels in a routine fashion using a single heating coil at each level. After the procedure, the patient wore lumbar brace for eight weeks and underwent physical therapy for six months. The patient's pain had significantly improved (3-4/10 NRS) at her twelve-week follow-up visit; she was off narcotic analgesics and was taking occasional NSAIDs. Six months after the IDET procedure, she was fully active and was back to her regular work.

## Discussion

These two case reports suggest that a treatment (IDET) which was targeted exclusively at the intervertebral discs, most likely led to the resolution of patients' pain. In addition to discal treatment these patients received analgesics, NSAIDs, physical therapy, epidural steroid injections, and lumbar brace. With the exception of epidural steroid injections and lumbar brace, the remaining therapies were continued before and after the discal treatments in a similar fashion. Discal treatments were not undertaken for several months after the epidural injections (two months in Case 1 and sixteen months in Case 2), and in both cases symptoms continued after the injections were given. Lumbar brace is generally an ineffective treatment for low back pain<sup>5</sup>. In both cases, however pain resolved in a predictable manner, ten to twelve weeks after the discal treatments. All of the above evidence indicates that discal treatments most likely led to resolution of patients' low back pain. Natural resolution of patients' pain is also unlikely; in both cases symptoms were present for a long and variable period (six months in Case 1, two years in Case 2) before the discs were treated. The response to treatments was sustained, and unlike a placebo response, that loses its efficacy with time<sup>6</sup>. If discal treatments most likely caused resolution of pain in these two cases, then it can also be concluded that their pain emanated from one or more intervertebral discs.

Intervertebral disc is often not considered a source of low back pain<sup>3</sup>. This assumption is often based on the fact that innervation of a normal disc is poor and is limited to the outer one third of the annulus<sup>7</sup>. Diagnosis of a painful disc is also a problem; a painful disc may appear relatively normal on routine spinal imaging<sup>8</sup>. In Case 1, the only abnormality visible on the MRI was loss of T-2 signal at L5-S1 level, such abnormalities are common in asymptomatic individuals<sup>8,9</sup>.

Further evaluation of these two patients by discography indicated that intervertebral discs were possible sources of pain. Post-discography CT also showed annular tears in the painful discs. Annular tears, however, were also seen when there was no pain or discordant pain on

provocative discography. Presence of annular tears alone on post-discography CT was, therefore insufficient evidence of a painful disc. Hence diagnosis of a painful disc by discography was based on pain provocation, confirming the subjective nature of this test<sup>10</sup>.

Disc pathology is generally described as degenerative in nature, however disc disruption may be an active, reversible process<sup>11</sup>. Dysfunction of disc cells results in loss of nuclear water content and consequently a reduction in disc height<sup>12</sup>. The disc annulus is then directly exposed to the compressive forces of the spine<sup>13</sup>. Direct annular compression may cause low backache, which is worse with axial loading. Annular compression will eventually lead to annular failure and fissuring. As disc disease evolves, there is growth of granulation tissue and pain fibers into the annular fissures, and an abnormal disc can become richly innervated by pain fibers<sup>7</sup>. A disc that is highly innervated by pain fibers and subject to abnormal compressive forces may become a source of chronic pain. Acute tears may also develop in failing annulus in the event of undue stress; such tears may be responsible for acute pain<sup>14</sup>. Pathological processes responsible for a painful disc therefore may not be uniform in nature; characteristics of pain produced by them and their natural history may also be different. An intervertebral disc has a limited capacity to repair itself<sup>15</sup>; a painful disc may, therefore remain a source of pain for a prolonged period of time. In addition, changes in the adjacent facet joints, spinal canal and sacroiliac joints, may further perpetuate the pain and disability from disc disease.

Current management of low back pain involves a process of exclusion; the initial step is often to exclude a herniated disc, fractures, infections, tumors and cauda-equina syndrome. Once these conditions are excluded, a common diagnosis of non-specific low back pain is made<sup>16</sup>. A number of patients with non-specific low back pain may have an undiagnosed painful disc. Undiagnosed and untreated, the disc may continue to be a source of pain and disc disruption cascade may continue to evolve. In addition to its disabling effects, patients with chronic low back pain may develop psychological, social and drug abuse problems. Treatment plans, based on an erroneous diagnosis may lead to inadequate

or inappropriate therapies. Without adequate explanation for their pain, patients are often dissatisfied with their physicians. The cost of untreated low back pain to the community may also be high, chronic low back pain remains the number one reason for patients on disability benefits and estimated loss of revenues from back pain remains in billions of dollars every year<sup>1</sup>.

The clinical features observed in these patients, in particular, pain worse with axial loading, tenderness over lower lumbar spinous processes, and limitation of range of motion of the low back, may be used in early clinical recognition of a painful disc. Considering the problems with spinal imaging and discography, a diagnostic test that can reliably detect a painful disc is needed. New treatment modalities are becoming available e.g. cellular transplantation, gene therapy, and tissue-engineering techniques, that may treat a painful disc and arrest further disc disruption<sup>17</sup>. Early diagnosis and treatment may, therefore prevent development of spinal, psychological, and social sequelae of a painful disc.

### **Conclusion**

Enigma of low back pain will continue until pain of discal origin is recognized and treated. Although based only on case reports, we provide strong arguments supporting the idea, that intervertebral discs can often be a source of low back pain. No diagnostic test currently exists that can reliably detect a painful disc. More research must be devoted to clear understanding of pathological processes by which an intervertebral disc can generate pain. Recognition and treatment of pain of discal etiology may reduce the enormous personal, social and national toll from low back pain.

## References

1. FRYMOYER JW, CATS-BARIL WL: An overview of the incidence and costs of low back pain. *Orthop Clin North Am*; 22:263-71, 1991.
2. SCHWARZER AC, APRIL CN, DERBY R, ET AL: The prevalence and clinical features of internal disc disruption in patients with chronic low back pain. *Spine*; 20:1878-83, 1995.
3. LEE KS, DOH JW, BAE HG, ET AL: Diagnostic criteria for the clinical syndrome of internal disc disruption: are they reliable? *Br J Neurosurg*; 17:19-23, 2003.
4. SACHS BL, VANHARANTA K, SPIVEY MA, ET AL: Dallas discogram description: a new classification of CT/discography in low-back disorders. *Spine*; 12:287-94, 1987.
5. JELLEMA P, VAN TULDER MW, VAN POPPEL MNM, ET AL: Lumbar support for prevention and treatment of low back pain. *Spine*; 26:377-86, 2001.
6. FEDELE L, MARCHINI M, ACAIA B, ET AL: Dynamics and significance of placebo response in primary dysmenorrhea. *Pain*; 36:43-7, 1989.
7. FREEMONT AJ, PEACOCK TE, GOUPILLE P, ET AL: Nerve ingrowth into diseased intervertebral disc in chronic back pain. *Lancet*; 350:178-81, 1997.
8. MILETTE PC, FONTAINE S, LEPANTO L, ET AL: Differentiating lumbar disc protrusions, disc bulges, and discs with normal contours but abnormal signal intensity. Magnetic resonance imaging with discographic correlations. *Spine*; 24:44-53, 1999.
9. VIDEMAN T, BATTIE MC, GIBBONS LE, ET AL: Associations between back pain history and lumbar MRI findings. *Spine*; 28:582-8, 2003.
10. NACHEMSON A: Lumbar discography-where are we today? *Spine*; 14:555-7, 1989.
11. FREEMONT AJ, WATKINS A, LE MAITRE C, ET AL: Current understanding of cellular and molecular events in intervertebral disc degeneration: implications for therapy. *J Pathol*; 196:374-9, 2002.
12. URBAN JP, MCMULLIN JF: Swelling pressure of the intervertebral discs: influence of proteoglycan and collagen contents. *Biorheology*; 22:145-57.
13. ADAMS MA, McNALLY DS, DONLAN P: Stress distributions inside intervertebral discs: the effects of age and degeneration. *J Bone Joint Surg [Br]*; 78:965-72, 1996.
14. MONETA GB, VIDEMAN T, KAIVANTO K, ET AL: Reported pain during lumbar discography as a function of annular ruptures and disc degeneration. *Spine*; 19:1968-74, 1994.
15. LIPSON SJ, MUIR H: 1980 Volvo award in basic science. Proteoglycans in experimental intervertebral disc degeneration. *Spine*; 6:194-210.
16. CARRAGEE EJ, HANNIBAL M: Diagnostic evaluation of low back pain. *Orthop Clin North Am*; 35:7-16, 2004.
17. AN HS, THONAR EJMA, MASUDA K: Biological repair of intervertebral disc. *Spine*; 28:S86-S92, 2003.