MUCOPOLYSACCHARIDOSES: ANESTHETIC CONSIDERATIONS AND CLINICAL MANIFESTATIONS

JERMALE A. SAM*, AMIR R. BALUCH**, RASHID S. NIAZ***, LINDSEY LONADIER*** AND ALAN D. KAYE****

Abstract

Mucopolysaccharidosis (MPS) is a group of genetic disorders that presents challenges during anesthetic care and in particular difficulty with airway management. Patients should be managed by experienced anesthesiologists at centers that are familiar with these types of conditions. Rarely encountered disease states have been identified as important topics in the continuing education of clinical anesthesiologists. This review will define MPS, describe the pathophysiology of MPS, describe how patients with this rare lysosomal storage disorders have dysfunction of tissues, cite the incidence of MPS, list the clinical manifestations and specific problems associated with the administration of anesthesia to patients with MPS, present treatment options for patients with MPS, define appropriate preoperative evaluation and perioperative management of these patients, including, to anticipate potential postoperative airway problems.

Introduction

Mucopolysaccharidoses (MPS) are a group of rare genetic lysosomal storage disorders characterized by the deficiency in or complete lack of necessary lysosomal enzymes required for the stepwise breakdown of glycosaminoglycans (GAGs, also known as mucopolysaccharidoses)[1-5]. Consequently, fragments of GAGs accumulate intracellularly in the lysosome resulting in cellular enlargement causing disruption/dysfunction of structure and function of tissues. This process leads to numerous clinical abnormalities. Incidence of all types of MPS is reported to be between 1in 10,000 to 1 in 30,000 live births and are transmitted autosomal recessive except for MPS II which is X-linked[1,4,5].

Pathophysiology

Glycosaminoglycans are long-chain complex carbohydrates consisting of repeating sulfated acidic and amino sugar disaccharide units. They are usually linked to proteins to form proteoglycans, which are the major

* Resident, Department of Surgery, Riverside Methodist Hospital, Columbus, Ohio.
** Attending Staff Physician, Metropolitan Anesthesia Consultants, Dallas, Texas.
*** Research Associate, Louisiana State University Health Science Center, New Orleans, Louisiana.
**** Professor and Chairman, Department of Anesthesiology, Louisiana State University Health Science Center, New Orleans, Louisiana.
Address Correspondence to: Alan D Kaye, MD, PhD, Professor and Chairman, Department of Anesthesiology, Louisiana State University School of Medicine, 1542 Tulane Ave, Room 656, New Orleans, LA 70112. Tel: (504) 568-2319, Fax: (504) 568-2317, E-mail: akaye@lsuhsc.edu

constituents of the ground substance of connective tissue, lubricant in joint fluid, and the surface coating that initially binds growth factors to cells. The major GAGs are chondroitin-4-sulfate, chondroitin-6-sulfate, heparan sulfate, dermatan sulfate, keratan sulfate, and hyaluronic acid. In the organism, these substances are degraded by the sequential action of lysosomal enzymes leading to a stepwise shortening of the terminal sulfate, acidic, and amino sugar residues. Deficient/dysfunctional activity of the degradative enzymes results in MPS disorder of which there are eleven types based on levels of severity. The clinical phenotype of the disorder depends upon the distribution and turnover of the substrate affected by the deficiency, rather than the distribution of the enzyme[1-6].

Classification

Of the 11 total MPS disorders, there are 7 major types classified I through IX. MPS V, formerly Scheie syndrome, and MPS VIII are no longer recognized[4]. The MPS disorders are differentiated by clinical features and age at presentation and biochemically by the associated enzyme deficiency. As a general rule, the impaired degradation of heparan sulfate is more closely associated with mental deficiency, and the impaired degradation of dermatan, chondroitin and keratan sulfate results in mesenchymal abnormalities[6,7]. Overall, these disorders can be grouped into four broad categories according to their dominant clinical features:

1. Soft tissue storage and skeletal disease with or without brain disease (MPS I, II,VII).
2. Soft tissue and skeletal disease (MPS VI).
3. Primarily skeletal disease (MPS IVa, IVb).
4. Primarily CNS disease (MPS IIIa-d).

Table 1

Specific classifications and features of MPS

Number	Eponym	Enzyme deficiency	GAG stored	Craniofacial abnormalities	Joint and skeletal deformities	Cardiac involvement	Visceral, visual, and neurologic manifesations
MPS I (severe)	Hurler syndrome	α -L-iduronidase	dermatan sulfate, heparan sulfate	macrocephaly coarse facies macroglossia hydrocephalus	stiff joints, thoracolumbar kyphosis, possible odontoid deformity, hypoplasia, short neck, short stature	coronary intimal and valvular thickening, mitral regurgitation, cardiomegaly	hepato-splenomegaly; umbilical and inguinal hernias; corneal clouding; severe mental retardation
MPS I (attenuated)	Scheie syndrome	α-L- iduronidase	dermatan sulfate, heparan sulfate	coarse facies, macroglossia prognathia	short neck, normal stature	aortic regurgitation	hepato-splenomegaly; umbilical and inguinal hernias; corneal clouding

MPS I (attenuated with different features)	Hurler-Scheie syndrome	α- L iduronidase	dermatan sulfate, heparan sulfate	macrocephaly, coarse facies, macroglossia, micrognathia	diffuse joint limitation, short neck, short stature	mitral and aortic value thickening and regurgitation	Hepato-splenomegaly, umbilical and inguinal hernias, corneal clouding
MPS II (severe)	Hunter syndrome (severe)	Iduronate sulfatase	dermatan sulfate, heparan sulfate	Macrocephaly, coarse facies, hydrocephalus	diffuse joint limitation, short neck, short stature	coronary intimal thickening, ischemic cardiomyopathy	hepato-splenomegaly, no corneal clouding
MPS II(attenuated)	Hunter syndrome(mild)	iduronate sulfatase	dermatan sulfate, heparan sulfate				
MPS IIIA (symptoms appear after the first year of life)	Sanfilippo A syndrome	Heparan N sulfatase	heparan sulfate	coarse facies, heavy eyebrows that meet in center of face above the nose	mild stiff joints, short stature, dysphagia	minimal to none	severe retardation, behavioral problems, diarrhea
MPS IIIB	Sanfilippo B syndrome	α– N acetyl glucosaminidase	heparan sulfate	coarse facies	mild stiff joints, short stature, walking problems, lumbar vertebral issues, dysphagia	minimal to none	developmental delay, behavioral problems
MPS IIIC	Sanfilippo C syndrome	acetyl Co α–glucosaminide acetlytransferase	heparan sulfate	coarse facies	mild stiff joints, short stature, lumbar vertebral issues, dysphagia	minimal to none	developmental delay, behavioral problems
MPS IIID	Sanfilippo D syndrome	N acetylglucosamine 6 sulfatase	heparan sulfate	coarse facies	mild stiff joints, short stature, lumbar vertebral issues, dysphagia	minimal to none	developmental delay, behavioral problems
MPS IVA	Morquio syndrome, type A	galactose 6 sulfatase	keratan sulfate, chondroitin-6-sulfate	coarse facies	joint laxity, severe kypho-scoliosis, odontoid hypoplasia, short neck, C1-C2, C2-C3 subluxation, short stature	aortic regurgitation	mild corneal opacities, hepato-splenomegaly
MPS IVB	Morquio syndrome, type B	beta galactosidase	Keratan sulfate, chondroitin-6-sulfate	coarse facies	joint laxity, severe kypho-scoliosis, odontoid hypoplasia, short neck, C1-C2, C2-C3 subluxation, short stature	aortic regurgitation	mild corneal opacities, hepato-splenomegaly

MPS VI	Maroteaux-Lamy syndrome	N-acetylgalactosamine-4-sulfatase	dermatan sulfate, heparan sulfate	Macrocephaly, coarse facies, macroglossia, hydrocephalus	mild joint stiffness, kyphoscoliosis, odontoid hypoplasia, short stature	mitral and aortic value thickening and regurgitation	
MPS VII	Sly syndrome	beta glucoronidase	dermatan sulfate, heparan sulfate, chondroitin 4,6 sulfate	Macrocephaly, coarse facies	joint flexion, contractures, thoracolumbar deformity, hip dysplasia, odontoid hypoplasia, short stature	mitral and aortic value thickening and regurgitation	
MPS IX		Hyaluronidase	Hyaluronan				

(Modified from Diaz JH, Belani KG. Perioperative management of children with mucopolysaccharidoses. Anesth Analg 1993; 77:1261-70).

Clinical Manifestations

As mentioned previously, MPS disorders are characterized by progressive craniofacial, joint, and skeletal deformities, progressive cardiac involvement, and early death from pulmonary infection or cardiac failure often before childhood[1-18]. Hurler syndrome is the prototypical MPS and occurs in 1 in 100,000 live births (Fig. 1)[13,14]. GAGs deposits lead to thickened heart valves, and valvular insufficiency more often than stenosis. Myocardial hypertrophy, ventricular dysfunction and cardiomyopathy result from accumulation of GAGs in the myocardium and frequently cause congestive heart failure and death. Intimal deposition of GAGs causes coronary luminal narrowing and occlusion that can be progressive[1-16]**.** GAGs are also deposited in abdominal viscera leading to hepatosplenomegaly (HSM) in most if not all patients. Umbilical and inguinal hernias can be due to abdominal protuberance from hepatospenomegaly. HSM and ineffective connective tissue support of the anterior abdominal wall often occurs. In addition to heart disease and HSM, most infants have chronic pulmonary disease caused by the thoracic cage restriction due to kyphoscoliosis, airway obstruction secondary to deposition of GAGs into the upper airway structures, recurrent pulmonary infection, pulmonary hypertension, and cardiomyopathy. Tongue protrusion and excessive tracheobronchial secretions are common[4-22].

Fig. 1

Patient with Hurler Syndrome, note his coarse facial features, crouched stance, thickened digits, and protuberant abdomen. This figure was taken from the following internet site: http://medgen.genetics.utah.edu/photographs/pages/hurler_syndrome.htm

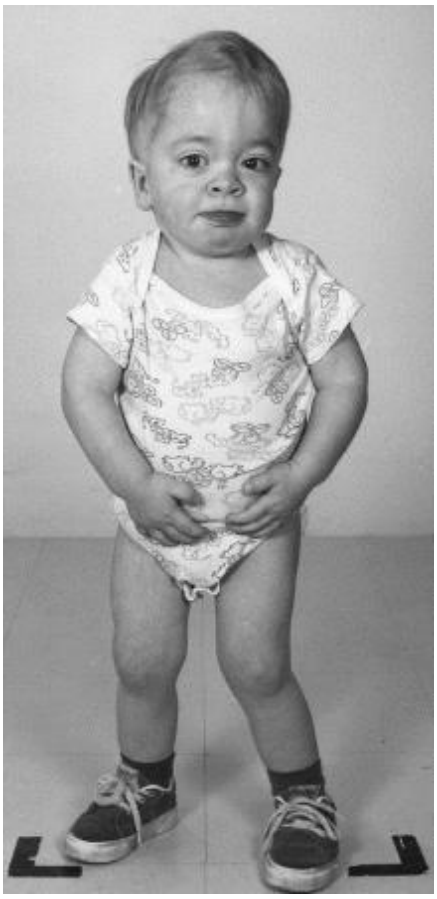

Diagnosis

A physician should be suspicious for MPS when a child presents with coarse facies, HSM, bone disease, and heart disease with or without CNS abnormalities[14,23,24]. However the initial presentation may be subtle and signs may be variable, depending on the type and severity of MPS. Measuring urinary GAG concentration can assist in identification of MPS but definitive diagnose is made by assay of enzyme activity from peripheral blood leukocytes. Additionally, skeletal radiographs may reveal the characteristic pattern of skeletal abnormalities known as dysostosis multiplex. An eye examination should be performed to assess corneal clouding and glaucoma which is most common in MPS I, II, VI and VII. A cardiac evaluation should be completed to adequately assess valvular and myocardial disease. A comprehensive neurologic examination estimates the potential for spinal cord compression and hydrocephalus[1-8,16].

Complications

Cardiopulmonary complications in patients with MPS are the most common cause of death[4].

Respiratory abnormalities are the result of airway obstruction, neurologic compromise, recurrent infections, skeletal restrictions, and/or organomegaly, all of which can lead to pulmonary insufficiency, severe

sleep apnea and sudden death from central apnea. MPS IV patients are especially prone to high cord compression secondary to atlantoaxial instability and odontoid dysplasia, which can lead to depressed respiration or sudden respiratory arrest. Cervical fusion is recommended. As previously stated, upper airway obstruction is also a cause of respiratory compromise. This obstruction can be due to redundant airway tissue caused by MPS deposition in the soft tissues of the nasopharynx. There may be enlarged tonsils and adenoidal tissue along with macroglossia and thickened gums. Secretions are excessive due to chronic or recurrent ear and sinus infections. Treatment focuses on maintenance of a stable airway. Obstruction can be temporarily reduced with removal of tonsils and adenoids along with the use of positive airway pressure[13,19].

Cardiac abnormalities are well documented. Valvular disease is caused by progressive thickening of the mitral and aortic valves and leads to insufficiency more often than stenosis. It is common in MPS I, II, VI. The defect typically results in heart failure and those severely affected may require valve replacement. Coronary vessel narrowing secondary to intimal deposition of MPS develops and impairs coronary vessel flow. Cardiac ischemia results. Pulmonary hypertension may exacerbate right heart failure[16,19].

Skeletal and connective tissue complications develop as GAG's accumulate in bones, joints, and ligaments. Dysostosis multiplex and odontoid hypoplasia are known to affect patients with MPS I, II, VI, VII and MPS I, IV and VII respectively. Hypoplasia can lead to atlantoaxial instability, C1-C2 subluxation, and high spinal cord compression. Measures for prophylactic cervical fusion should be undertaken to prevent progressive cord compression. Patients also suffer from vertebral subluxation and kyphoscoliosis throughout the spinal column which can compromise the spinal cord and may need spinal fusion for stabilization. Unfortunately, patients typically heal poorly from such surgeries and often have complications requiring repeat surgery. Short stature is also a common finding throughout the spectrum of MPS types. Very often, patients present with joint stiffness, secondary to accumulation of MPS in the synovial fluid and other connective tissues of the joints[24-28].

Gastrointestinal complications include recurring inguinal and umbilical hernias and hepatosplenomegaly with increased intrabdominal pressure. Surgical repair is often performed and may have to be repeated[13,16,19].

Neurological complications are well documented. Developmental delay and progressive neurologic decline occur in the severe form of MPS I, II, III, and VII. Communicating hydrocephalus frequently develops in MPS I, II, III, VI, and VII due to the engorgement of arachnoid granulations by storage material, impeding resorption of cerebrospinal fluid and increasing intracranial pressure. In MPS III, hydrocephalus is secondary to ventricular enlargement due to cerebral atrophy in the later stages of the illness. Pachymeningitis cervicalis, a progressive thickening and scarring of the meninges around the cervical spinal cord caused by accumulation of MPS, is another neurologic complication. This thickening may form a sleeve around the spinal cord that impedes the flow of cerebrospinal fluid (CSF) and progressively compresses the cervical cord. Cord compression from pachymeningitis cervicalis and odontoid dysplasia can result in progressive ascending paresis and paralysis[13,18].

Opthalmic and auditory complications are common. Ophthalmologic manifestations include corneal clouding and potentially blindness may develop. Eye examinations should be performed at the time of diagnosis and annually thereafter[29,30]. Auditory manifestations include conductive and neurosensory deafness. Hearing loss may be attributable to frequent ear infections, defective ossification in the middle ear, scarring of the tympanic membrane, or nerve damage. Annual audiologic exams are warranted and are particularly important for patients with MPS I. Hearing aids are beneficial[31,32].

Therapy

Treatment for MPS disorders is usually symptomatic and not specific. Bone marrow transplantation (BMT) has been used to successfully treat some of the disorders in the spectrum of MPS. In most patients with successful engraftment, transplantation reduces hepatosplenomegaly, increases joint mobility, decreases airway obstruction, improves cardiac function, decreases CSF pressure, and especially in younger patients, may stabilize mental regression. Unfortunately, BMT does not correct skeletal disorders nor prevent CNS decline in severe cases. Immunosuppressant treatment is required. The therapy is routinely offered only to MPS patients with Hurler syndrome under approximately two years of age. It is less commonly used in mild MPS II, VI, and VII. Cord blood transplantation is another potential source for transplantation[22].

Emerging treatments for MPS beyond BMT include enzyme replacement therapy (ERT), substrate reduction therapy (SRT), chaperone-mediated therapy, and gene therapy. Although complete clinical efficacy has not yet been completely seen for any of these therapies, it appears that future developments will lead to a disease-modifying treatment[33,34]. Enzyme replacement therapy with recombinant iduronate-2-sulphatase (idursulfase) is being clinically investigated and weekly intravenous infusions of idursulfase improve many of the symptoms and signs of MPS[33].

Anesthesia Considerations

Preoperative evaluation

Considerations include assessment of neurologic function, anticipation of a difficult airway and ventilatory management, cardiac complications, skeletal disease, and visceral manifestations[1,2,13,16]. Chest x-ray, arterial blood gas analysis and pulmonary functions tests may be indicated in patients with chronic pulmonary infections and/or kyphoscoliosis. Vital capacity, functional residual capacity, and total lung capacity are often reduced by skeletal restrictions. Preoperatively, the goal should be to optimize lung capacity and may include physiotherapy, pulmonary toilet, and/or antibiotics if infection is present[1,2,13,16]. To assess clinically relevant spinal disease, radiographs should be performed to identify atlantoaxial subluxation, especially in patients with Morquio and Hurler syndromes. Flexion-extension cervical films may confirm the potential for subluxation and demonstrate tracheal collapse on flexion. Atlantoaxial subluxation contraindicates cervical extension during endotracheal intubation. Spinal cord compression due to subluxation frequently occurs within the spectrum of MPS. Patients presenting with clinical manifestations such as abnormal gait, sensory changes, or weakness in lower extremities should be evaluated by a neurologist[1,2,13,16]. Somatosensory evoked potentials can be used to detect early cord compression and guide the timing of surgical intervention. Patients with MPS I who undergo spinal surgery are at increased risk of major complications, including spinal cord infarction and spinal instability. Communicating hydrocephalus can be seen, and if suspected, measurement of CSF pressure should be considered. With increased ICP, ventriculostomy may successfully reduce CSF pressure but typically does not reverse clinical disease significantly[1,2,13,16]. An enlarged heart and pulmonary congestion should prompt evaluation by 2D echocardiography, which can detect right ventricular hypertrophy with strain, conduction blocks, left atrial enlargement, tachydysrhythmias, and ischemic changes. Systolic murmurs are common and this too should prompt evaluation by echocardiography. If patients experience chest pain or clinical symptoms

that suggest ischemia, more invasive diagnostic tests are indicated such as angiography. Case reports have suggested that the contribution of cardiac involvement, particularly mitral insufficiency and cardiomegaly, in stress tolerance related to anesthetic management was minimal; however, a few instances have pointed to severe and extensive coronary obstruction as a cause for two intra-operative deaths[10,13]. Patients with moderate/severe skeletal disease should have ongoing monitoring by an orthopedic surgeon. Spine deformities may require fusion; acetabular hip dysplasia can be managed with osteotomy and genu valgum with epiphyseal stapling. Carpal tunnel release can provide relief and the return of some hand function[1,2,13,16]. Visceral manifestations are common. Inguinal hernias are commonly repaired before disease diagnosis. Umbilical hernias often recur, due probably to hepatosplenomegaly. Since the most common clinical manifestations include chronic upper respiratory infections, it is important to identify any potential infectious processes. Tonsillectomy and adenoidectomy should be considered for all patients who develop airway compromise. For patients with MPS, they are typically evaluated for routine ear, nose, and throat exams annually; however, careful preanesthethic assessment may be invaluable if underlying pathophysiological process are subclinical and have not been identified[1,2,13,16].

Anesthesia Drug Considerations

Premedication sedation should be used cautiously if at all because of the risks of upper airway obstruction, respiratory depression, hypercarbia, and cardiorespiratory arrest. Opioids should be avoided if airway problems are anticipated because of respiratory depression. Oropharyngeal secretions can be controlled be anticholinergics, such as scopolamine or glycopyrrolate[3,6,10,13]. Hurler syndrome being the prototypical form and most severe disorder has an incidence of difficult tracheal intubation as high as 50%. Some authors suggest intravenous induction for younger patients with lesser degrees of craniofacial involvement and inhaled inductions in older patients with established or anticipated airway difficulties[3,6,10]. Others maintain that inhalation induction is preferable; however, intravenous induction may be necessary for the severely retarded and uncooperative patient. Many authors suggest induction with intramuscular ketamine over inhalation induction[3,6,10].

MPS patients seem not to be at increased risk for malignant hyperthermia. Maintenance anesthesia is usually with an inhalational agent[3,6,10]. The muscle relaxant of choice is often a short acting non-depolarizing muscle relaxant.

Airway Management

Patients with MPS may be difficult to ventilate secondary to abnormal facies. An air-cushioned pediatric face-mask may be applied upside down, with the broad chin edge of the mask over the patient's brow and nose and the narrow nasal bridge of the mask over the open mouth and protruding tongue[13]. Advanced airway management instruments should be available including an assortment of face masks, endotracheal tubes, laryngoscope blades and handles, fiberoptic equipment, Glidescope®, the difficult airway cart, and even a surgeon standing by ready to do an emergency tracheostomy. Direct laryngoscopy for awake orotracheal intubation will be difficult. Airway manipulation is much easier to perform in deeply sedated spontaneously ventilating patients[13]. As mentioned above, atlantoaxial subluxation secondary to odontoid hypoplasia/dysplasia with spinal cord and brainstem compression may occur during cervical hyperextension[13]. Cervical traction can

be used to prevent manipulation of the neck. Since deposits make it extremely difficult to feel the trachea, utilization of retrograde catheter-guided tracheal intubation is not recommended. Blind nasotracheal intubation and tracheostomy carry significant risks and are recommended only in emergency situations. Some authors believe that fiberoptic bronchoscope should be available for all known difficult intubations presenting for anesthetic management[13].

Postoperative Management

The emerging child may experience difficulty breathing against the high airway resistance of an endotracheal tube. Pulmonary hypertension can be exacerbated and negative pressure pulmonary edema may ensue and require immediate management including mechanical ventilatory support. Multiple attempts at intubation should be avoided because they can lead to symptomatic glottic and subglottic edema. Such iatrogenic conditions are very difficult to treat due to the progressive narrowing of the tracheal lumen by MPS deposits[10,13]. Utilizing a fiberoptic intubation and then leaving the endotracheal tube in place immediately postoperatively, minimizes airway complications, in particular for those patients who do not meet all the extubation criteria. After tracheal extubation, humidified O2, chest physiotherapy, and postural drainage should be instituted and continued until the patient is ambulatory and able to expectorate excessive secretions[10,13].

Conclusions

Patients presenting with MPS are often difficult to manage peri-operatively and though new treatments are providing hope, many challenges remain. Understanding the pathophysiology of this group of diseases increases awareness of the potential risks of anesthesia and surgery. Ideally, children with MPS should be managed by anesthesiologists familiar with the disease process to minimize complications and reduce morbidity and mortality.

References

1. WALKER RW, DAROWSKI M, MORRIS P, WRAITH, JE: Anaesthesia and mucopolysaccharidoses. A review of airway problems in children. *Anaesthesia*; 1994, 49:1078-84.
2. BAINES D, KENEALLY J: Anaesthetic implications of the mucopolysaccharidoses: a fifteen year experience in a children's hospital. *Anaesth Intensive Care*; 1983, 11:198-202.
3. HERRICK IA, RHINE EJ: The mucopolysaccharidoses and anaesthesia: a report of clinical experience. *Can J of Anaesth*; 1988, 35:67-73.
4. NEUFELD EF, MUENZER J, ET AL: The mucopolysaccharidoses. In: Scriver C, Beaudet A, Sly W, et al., editors. *The metabolic and molecular bases of inherited disease*. 8. New York: McGraw-Hill; 2001, pp. 3421-3452.
5. WAPPNER RS: Lysosomal Storage Disorders. In: McMillan JA, Feigin RD, et al., editors. Oski's *Pediatrics Principles and practice*. 4. Pennsylvania: JB Lippincott Co, 2006, pp. 2199-2217.
6. SJORGREN P, PEDERSEN T, STEINMETZ H: Mucopolysaccharidoses and anesthetic risks. *Acta Anaesthesiol Scand*; 1987, 31:214-218.
7. WRAITH JE: The mucopolysaccharidoses: a clinical review and guide to management. *Arch Dis Child;* 1995, 72:263-267.
8. MUENZER J: Mucopolysaccharidoses. *Adv Pediatr*; 1986, 33:269-302.
9. SEMENZA GL, PYERITZ RE: Respiratory complications of mucopolysaccharide storage disorders. *Medicine (Baltimore)*; 1988, 67:209-219.
10. BELANI KG, KRIVIT W, CARPENTER BL, ET AL: Children with mucopolysaccharidoses: perioperative care, morbidity, mortality, and new findings. *J Pediatr Surg*; 1993, 28:403-408.
11. KEMPTHORNE PM, BROWN TC: Anaesthesia and the mucopolysaccharidoses: a survey of techniques and problems. *Anaesth Intensive Care*; 1983, 11:203-207.
12. MOORES C, ROGERS JG, MCKENZIE IM, ET AL: Anaesthesia for children with mucopolysaccharidoses. *Anaesth Intensive Care*; 1996, 24:459-463.
13. DIAZ JH, BELANI KG: Perioperative Management of children with mucopolysaccharidoses. *Anesth Analg*; 1993, 77:1261-70.
14. Wraith JE: The first 5 years of clinical experience with laronidase enzyme replacement therapy for mucopolysaccharidosis I. *Expert Opin Pharmacother*; 2005, 6(3):489-506.
15. KING DH, JONES RM, BARNETT MB: Anaesthetic considerations in the mucopolysaccharidoses. *Anesthesia*; 1984, 39:126-31.
16. MUENZER J, WRAITH JE, CLARKE LA: International Consensus Panel on Management and Treatment of Mucopolysaccharidosis I. Mucopolysaccharidosis I: Management and treatment guidelines. *Pediatrics*; 2009, 123:19-29.
17. WALKER RW, COLOVIC V, ROBINSON DN, ET AL: Case Report: Postobstructive pulmonary oedema during anaesthesia in children with mucopolysaccharidoes. *Paediatr Anaesth*; 2003, 13:441-447.
18. LINSTEDT U, MAIER C, JOEHNK H, ET AL: Threatening spinal cord compression during anesthesia in a child with mucopolysaccharidosis VI. *Anesthesiology*; 1994, 80:227-229.
19. BUTLER MG, HAYES BG, HATHAWAY MM, ET AL: Specific Genetic Diseases at Risk for Sedation/Anesthesia complications. *Anesth Analg*; 2000, 91:837-55.
20. SJORGEN P, PEDERSEN T: Anaesthetic problems in Hurler-Scheie syndrome. Report of two cases. *Acta Anaesthesiol Scand*; 1986, 30:484-6.
21. MUENZER J: The mucopolysaccharidoses: A heterogeneous group of disorders with variable pediatric presentations. *J Pediatr*; May 2004, 144:S27-34.
22. VELLODI A, YOUNG EP, COOPER A, ET AL: Bone marrow transplantation for mucopolysaccharidosis type I: Experience of two British centres. *Arch Dis Child*; 1997, 76:92-99.
23. VIJAY S, WRAITH JE: Clinical presentation and follow-up of patients with the attenuated phenotype of mucopolysaccharidosis type I. *Acta Paediatr*; 2005, 94(7):872-877.
24. WENGER DA, COPPOLA S, LIU SL: Insights into the diagnosis and treatment of lysosomal storage diseases. *Arch Neurol*; 2003, 60(3):322-328.
25. MEIKLE PJ, HOPWOOD JJ, CLAGUE AE, CAREY WF: Prevalence of lysosomal storage disorders. *JAMA*; 1999, 281(3):249-254.
26. STEVENS JM, KENDALL BE, CROCKARD HA, RANSFORD, A: The odontoid process in Morquio-Brailsford's disease. The effects of occipitocervical fusion. *J Bone Joint Surg Br;* 1991, 73:851.
27. TANDON V, WILLIAMSON JB, COWIE RA, WRAITH JE: Spinal problems in mucopolysaccharidosis I (Hurler syndrome). *J Bone Joint Surg Br*; 1996, 78:938.
28. JONES KL: Storage disorders. In: Smith's Recognizable Patterns of Human Malformation. 6. Philadelphia, Pa: WB Saunders Co, 2005, 452-471.
29. ASHWORTH JL, BISWAS S, WRAITH E, LLOYD CI: Mucopolysaccharidoses and the Eye. *Survey of ophthalmology*; Jan 2006, 51(1):1-17.
30. KOTTLER U, DEMIR D, SCHMIDTMANN I, BECK M, PITZ S: Central Corneal Thickness in Mucopolysaccharidosis II and VI. *Cornea. Mar*; 2010, 29(3):260-2.
31. HAYES E, BABIN R, PLATZ C: The otologic manifestations of mucopolysaccharidoses. *Am J Otol*; 1980, 2:65-69.

32. RUCKENSTEIN MJ, MACDONALD RE, ET AL: The management of otolaryngological problems in the mucopolysaccharidoses: a retrospective review. *J Otolaryngol*; 1991, Jun, 20(3):177-83.
33. BECK M: Mucopolysaccharidosis Type II (Hunter Syndrome): Clinical Picture and Treatment. *Curr Pharm Biotechnol*; 2011, *in press*.
34. DE RUIJTER J, VALSTAR MJ, WIJBURG FA: Mucopolysaccharidosis Type III (Sanfilippo Syndrome): Emerging Treatment Strategies. *Curr Pharm Biotechnol*; 2011, *in press*.