

## PERSISTANT DYSPHONIA FOLLOWING ENDOTRACHEAL INTUBATION\*

ABDUL-LATIF HAMDAN<sup>\*</sup>, OMAR SABRA<sup>\*\*</sup>,  
CHARBEL RAMEH<sup>\*\*</sup> AND MOHAMAD EL-KHATIB<sup>\*\*\*</sup>

### **Abstract**

Voice production is a complex process that involves more than one system, yet most causes of dysphonia are attributed to disturbances in the laryngeal structures and little attention is paid to extralaryngeal factors. Persistent dysphonia after general anesthesia is a challenge to both anesthesiologists and otolaryngologists. The etiology is often multivariable and necessitates a team approach for proper diagnosis. Laryngeal symptoms are subdivided into phonatory disturbances and airway related complaints.

When they become persistent for more than 72 hours or are coupled with airway symptoms such as hemoptysis, stridor, dyspnea or aspiration, the anesthesiologist should suspect injury to the vocal folds or cricoarytenoid joints.

Here-below, the laryngeal manifestations of endotracheal intubation and the pathophysiology of vocal fold scarring are discussed.

### **Introduction**

Dysphonia or change in voice quality reported by the patient following surgery is very often overlooked by the anesthesiologist and the treating physician. In view of its transient nature, no investigation for the

---

\* Clinical Associate Professor-Department of Otolaryngology-Head & Neck Surgery.

\*\* Resident-Department of Otolaryngology-Head & Neck Surgery.

\*\*\* Associate Professor-Department of Anesthesiology.

Corresponding Author: Dr. Mohamad Khatib, American University of Beirut, Department of Anesthesiology, E-mail: mk05@aub.edu.lb.

causes of dysphonia is warranted despite the frequency of this condition. The diagnosis is always late and the etiology invariably is attributed to factors related to anesthesia<sup>1</sup>.

Voice production is a complex process that involves more than one system and the human phonatory behavior requires more than simple oscillation of the vocal folds. Adequate breathing support and control are a must to initiate the vocal signal and resonance is needed for proper amplification and projection of the sound. The power supply for vocal production may be affected in chest or abdominal surgery, yet most causes of dysphonia are attributed to disturbances in the laryngeal structure and little attention is paid to extralaryngeal factors.

When should the anesthesia team suspect laryngeal injury post-operatively? What are the alarming symptoms that should prompt early investigation of dysphonia?

A discussion on the laryngeal manifestations of endolaryngeal manipulation during general anesthesia is presented together with the common etiologic factors.

## **Discussion**

Persistent dysphonia after general anesthesia is a challenge to both anesthesiologists and otolaryngologists. The etiology is often multivariable and necessitates a team approach for proper diagnosis. Poor breath support or muscle tension patterns are often present, which makes the glottic contribution to dysphonia postoperatively not always clear.

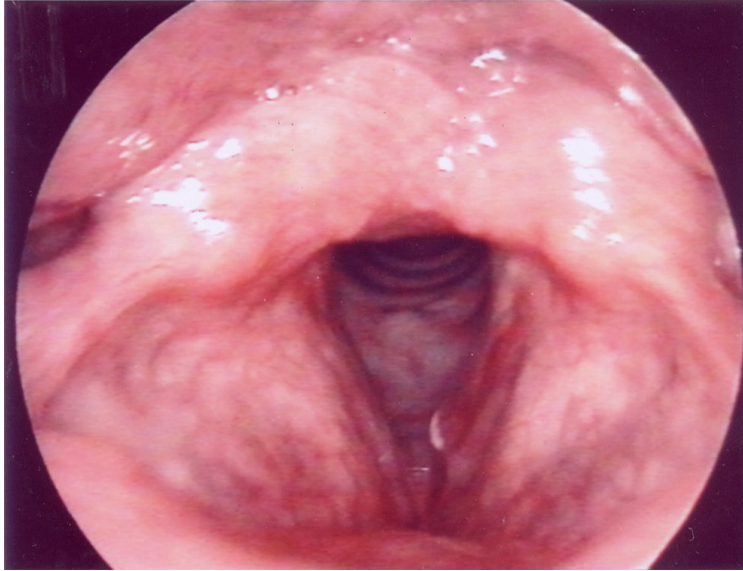
The etiology of dysphonia following general anesthesia can be subdivided into laryngeal and extralaryngeal. Laryngeal symptoms are either phonatory disturbances or related to airway complaints. The phonatory disturbances may be reported or perceived by professional listeners as hoarseness or dysphonia, breathiness, complete aphonia, vocal fatigue, pitch breaks, inability to sustain phonation and volume disturbances. Other symptoms may include sore throat, fullness and foreign body sensation. Most of these phonatory symptoms are substantiated by an increase in the perturbation parameters which reflect

cycle to cycle variations in the intensity and frequency of the vocal folds vibration<sup>2,3,4</sup>. When these phonatory symptoms are present, it is important to note that they are self limited and subside within 24 to 48 hours. When they become persistent for more than 72 hours, the anesthesiologist should suspect injury to the vocal folds. When the phonatory symptoms are coupled with airway symptoms such as stridor, dyspnea or aspiration, cricoarytenoid joint injury is highly on the list which mandates prompt assessment of the upper airway. In these cases, phonatory dysfunction is invariably associated with a degree of laryngeal trauma that varies between 5 to 80% pending on the mode of laryngeal assessment<sup>5,6</sup>. Telescopic examination provides an excellent illuminated picture that will allow visualization of the laryngeal anatomy and the presence or absence of any glottic or supraglottic lesion. Fiberoptic laryngeal endoscopy on the other hand will enable us to study the laryngeal biomechanics of the speaking voice, i.e. the behavior of laryngeal structures in relation to time and how they interact with vocal fold injury. Laryngeal video-stroboscopy will reflect on the property of the vocal fold cover during vibration. Parameters such as amplitude (extent of lateral excursion of the vocal folds), closure and mucosal waves are measured. A stroboscopic study by Preshel et al revealed a decrease in the mucosal waves and propagation in patients following endotracheal intubation<sup>7</sup>.

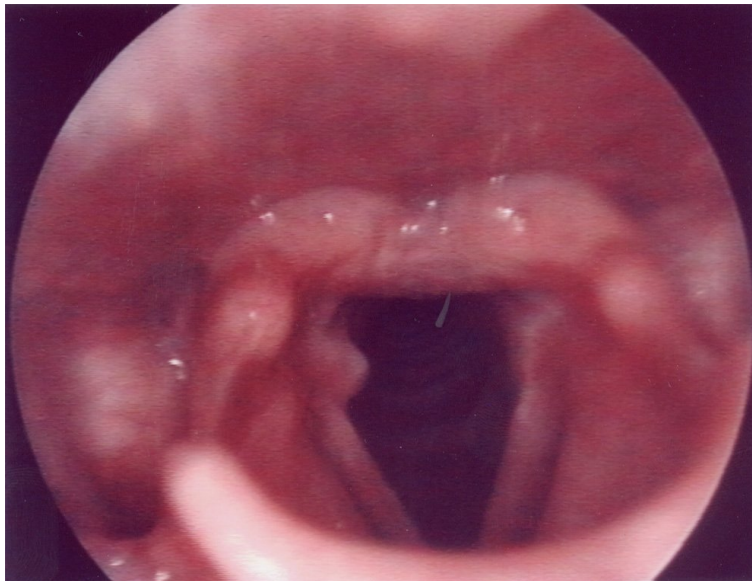
The degree of laryngeal trauma following endotracheal manipulation may extend from simple edema or redness of the vocal folds, hematoma of the vocal folds, to dislocation of the arytenoid cartilages<sup>8</sup>. Other findings may include vocal fold laceration, avulsion of the vocal process of the arytenoids, and granulation tissue (Figure 1 & 2).

A proper respect of the Reinke's space, the superficial layer of the lamina propria, is crucial for the vibration of the vocal fold and empirical in the prevention of dysphonia following endolaryngeal manipulation. The body-cover theory initially described by Hirano and Kakita, clearly illustrates the importance of the vocal pliability in voice production<sup>9</sup>. The violation of this structural layer by aggressive intubation may result in stiffness of the vocal fold with subsequent dysphonia that is persistent. It is important to understand

*Fig. 1*  
*Right vocal process granulation tissue*



*Fig. 2*  
*Hematoma of the right vocal fold with polypoid degeneration*



that vocal fold scarring following intubation is an ongoing tissue remodeling process highly mediated by many interstitial proteins. There is an increase in pro-collagen and collagen production, which migrate from the deep layer of the lamina propria. There is also alteration in the interstitial proteins and elastic fibers which become more erratic and broken. As a result of these alterations in the extra cellular matrix proteins, the viscoelastic properties of the tissues change<sup>10,11</sup>. When scarring and fibrosis of the vocal folds occur, the fluid like layer of the Reinke's space is gone and instead there is stiffness which reduces vocal cord vibration. This is observed on laryngeal video-endostroboscopy as reduced mucosal waves or the presence of an adynamic segment.

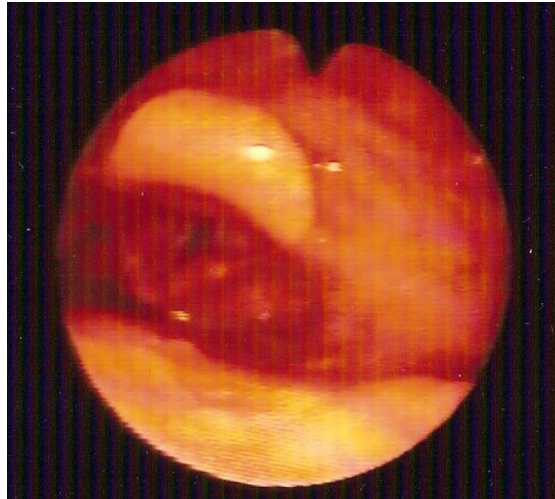
In cases of scarring and fibrosis of the vocal fold, patients need to start voice therapy as an initial approach. This will help him or her to develop appropriate voice behaviors and prevent hyperfunctional compensatory disorders. When significant improvement does not occur secondary to a wide glottal gap, extreme vocal fold stiffness or simply poor patient's compliance, other surgical measures should be taken. In the rehabilitation of such a problem, the operative options are limited. To restore the pliability of the vocal fold, the superficial layer of the lamina propria needs to be substituted. Isshiki et al described surgical mucosal grafting<sup>12</sup>. Ford et al has injected collagen material whereas Mikus et al has used fat instead<sup>13,14</sup>. Other materials such as gelfoam and recently hyaluronic acid have also been used for that purpose. Fat injection into the vocalis muscle for augmentation has been used for a long time<sup>15</sup>, but for scar treatment only in the last decade or so. Submucosal fat implantation into Reinke's layer has proved not only restoration of vocal fold vibration but also long term viability. Fat implantation obviates the need for fat processing which is believed to be the major cause of cell necrosis. All of this has propelled the usage of fat as a soft tissue implant for rehabilitation of the scarred larynx<sup>16</sup>. Another surgical option that is kept in mind for the adynamic vocal fold with incomplete glottic closure is medialization laryngoplasty. It is important in these cases not to introduce a posterior phalange that may hinder the arytenoids mobility.

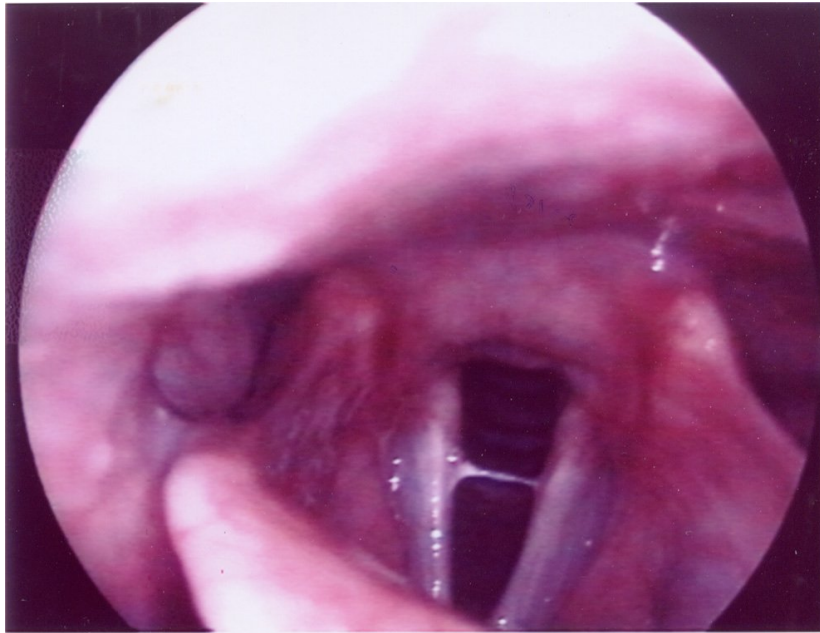
Another important cause of persistent dysphonia following general

anesthesia is the presence of a fixed vocal fold. This later does not always mean dislocation of the arytenoids but could be secondary to vocal fold paralysis. Arytenoid dislocation or sublaxation may occur either during intubation or extubation. Aggressive intubation with a large endotracheal tube or when the endotracheal tube is inserted while the vocal folds are still in the median position, may injure both the vocal folds and the cricoarytenoid joints. Similarly, removal of the endotracheal tube while the cough is still inflated may dislodge the arytenoids and result in an incompetent glottis<sup>2,5</sup>. On the other hand, vocal fold paralysis invariably is secondary either to hyperinflation of the endotracheal tube cough, aggressive extension of the neck or simply the insertion of a subclavian central line on the right side. The injury is usually self limiting and does not extend beyond neuropraxia. Laryngeal electromyography can differentiate cricoarytenoid joint dislocation or fixation from vocal fold paralysis (Figure 3).

Another important factor to consider in the examination of the larynx is the extent of mucus, its consistency and behavior with vocal fold oscillation. A change in the consistency of the mucus reflects either an element of dehydration that is systemic and secondary to medications such as atropine or to the local drying effect of anesthetic agents<sup>17,18</sup> (Figure 4).

*Fig.3*  
*Fixed right vocal fold*



*Fig. 4**Thick mucus streak between vocal folds*

Phonatory symptoms are not always the manifestations of a laryngeal pathology. General anesthesia can disturb the laryngeal behavior also by affecting the pulmonary system, an important denominator for voice production. Breathing support may be diminished post-operatively either due to musculoskeletal tenderness and pain or secondary to lung atelectasis or collapse. More so, restricted ventilation has been reported in up to 48 hours post-operatively after the intake of narcotics and barbiturates. General anesthesia may also affect the fine motor control and sensorium of the laryngeal neuromuscular activity, resulting in an increase in the perturbation parameters with consequent dysphonia<sup>19,20</sup> (Table 1).

Table 1

<b>Laryngeal Manifestations of Endotracheal Intubation</b>		
Laryngeal Findings	Symptoms	Etiology
VF edema/Redness	Throat clearing, hoarseness	Intubation, ET factors (size, material, cuff)
Arytenoid edema/redness	No symptoms, throat clearing Globus Pharyngus	
Vocal fold Hematoma, Laceration	Aphonia, severe dysphonia	Traumatic intubation/extubation
Arytenoid subluxation/dislocation Avulsion of vocal process of arytenoid	Breathiness, Aspiration, dysphonia	Traumatic intubation/extubation
Vocal fold dryness Alterations in Rheologic properties of vocal fold cover	Xerophonia (Dry voice) Vocal fatigue Increase in phonatory effort	Anesthetic gas Drying medication Dehydration
Vocal fold paralysis	Breathiness Aspiration	Hyperextension of neck Hyperinflation of ET cuff Insertion of subclavian line (RT)

## References

1. BECKFORD NS, MAYO R, WILKINSON A III, TIERNEY M: Effects of short endotracheal intubation on vocal function. *Laryngoscope*; 100:331-6, 1990.
2. PEPPARD S, DICKENS J: Laryngeal injury following short term intubation. *Ann Otol Rhinol Laryngol*; 92:327-30, 1983.
3. KEANE W, ROWE L, DENNENY J, ATKINS J: Complications of intubation. *Ann Otol Rhinol Laryngol*; 91:584-7, 1982.
4. HEDDEN M, ERSOZ CJ, DONNELLY HW, SAFAR P: Laryngotracheal damage after prolonged use of orotracheal tubes in adults. *JAMA*; 207:703, 1977.
5. WEYMULLER E, BISHOP M: Problems associated with prolonged intubation in the geriatric patient. *Otolaryngol Clin N Amer*; 23:1057-74, 1990.
6. BALESTRIERI F, WATSON C: Intubation granuloma. *Otolaryngol Clin N Amer*; 15:567-79, 1982.
7. PRESCHER U, EYSHOLDT U: Kurzzeit-Veränderungen an Kehlkopf und Stimme nach Intubation. *Laryngo Rhino Otol*; 72:93:7, 1993.
8. BISHOP M: Mechanisms of laryngotracheal injury following prolonged tracheal intubation. *Chest*; 96:185-6, 1989.
9. HIRANO M, KAKITA Y: Cover-body theory of vocal cord vibration. In Daniloff RG, ed. *Speech Science*. San Diego, California: College Hills Press, 1-46, 1985.
10. BENNINGER M, ALESSI D, ARCHER S, BASTIAN R, FORD C, KOUFMAN J, SATALOFF RT, SPIEGEL J, WOO P: Vocal fold scarring: Current concepts and management. *Otolaryngol Head Neck Surg*; 115:474-82, 1996.
11. OKAMURA H, YUMOTO E, OKAMOTO K: Wound healing of canine vocal folds after phonosurgery. *Ann Otol Rhinol Laryngol*; 96:425-8, 1987.
12. ISSHIKI N: *Surgical Management of Scar of the Vocal Cord in Phonosurgery: Theory and practice*. Berlin, Germany: Springer Verlag, 175-9, 1989.
13. FORD C: Laryngeal injection techniques in phono surgery. In: Ford CN, Bless DM, eds. *Assessment and Surgical Management of Voice Disorders*. New York, NY: Raven Press, 123-41, 1991.
14. MIKUS JL, KOUFMAN JA, KILPATRICK SE: Fate of liposuctioned and purified autologous fat injections in the canine vocal fold. *Laryngoscope*; 105:17-22, 1995.
15. WETMORE S: Injection of fat for soft tissue augmentation. *Laryngoscope*; 99:50-7, 1989.
16. WOO P, RAHBAR R, WANG Z: Fat implantation into Reinke's space: a histologic and stroboscopic study in the canine. *Ann Otol Rhinol Laryngol*; 108:738-44, 1999.
17. FINKELHOR BK, TITZE IR, DURHAM PL: The effect of viscosity changes in the vocal folds on the range of oscillation. *J Voice*; 1:320-325, 1988.
18. BLESS D, SHAIKH A: The effect of Atropine on voice production. Presented at the State Medical Society of Otolaryngology, Milwaukee, WI, 1986.
19. TOLICS MD ET AL: Lung collapse and gas exchange during general anesthesia: Effects of spontaneous breathing, muscle paralysis and positive end-expiratory pressure. *Anesthesiology*; 66:157, 1987.
20. CARTWRIGHT MB, ET AL: Ventilatory depression related to plasma fentanyl concentrations during and after anesthesia in humans. *Anesth Analg*; 62:966-974, 1983.

