

# ULTRASONOGRAPHIC MODIFICATION OF CORMACK LEHANE CLASSIFICATION FOR PRE-ANESTHETIC AIRWAY ASSESSMENT\*

DEEPAK GUPTA, ARVIND SRIRAJAKALIDINDI, BRYANT ITTIARA,  
LEIGH APPLE, GOKUL TOSHNIWAL, HALIM HABER

## Abstract

*Background:* The major drawback of Cormack Lehane classification for airway assessment is its dependence on invasive direct laryngoscopy and hence it is inapplicable for pre-anesthetic assessment of airway in patients with no prior history of tracheal intubation.

*Study Objectives:* The purpose of the study was to compare and correlate the ultrasound view of the airway and the Cormack Lehane classification of the direct laryngoscopy.

*Methods/Study Procedures:* The present study was conducted on patients scheduled for elective surgery and requiring general anesthesia with direct laryngoscopy and endotracheal intubation. In the pre-operative holding area, the following measurements were obtained with the oblique-transverse ultrasound view of the airway: (a) the distance from the epiglottis to the midpoint of the distance between the vocal folds, (b) the depth of the pre-epiglottic space, and (c) the total time taken by the operator to achieve the final ultrasonic image. The data was then compared with the Cormack Lehane classification during direct laryngoscopy in the operating room. Subsequently based on the correlation data, the ultrasonographic modification of Cormack-Lehane Classification was developed.

*Results:* It was observed that there was a correlation of the distance between the epiglottis and the vocal cords (E-VC) with the Cormack Lehane Grading; correlation was strong negative with regression coefficient of -0.966 (95% CI -1.431 to -0.501;  $p = 0.0001$ ). Subsequently, the correlation of the pre-epiglottis space (Pre-E) with the Cormack Lehane Grading was strong in positive direction with regression coefficient of 0.595 (95% CI 0.261 to 0.929;  $p = 0.0008$ ). Finally the ratio of Pre-E and E-VC distances with the Cormack Lehane Grading had the strongest positive correlation with regression coefficient of 0.495 (95% CI 0.319 to 0.671;  $p < 0.0001$ ). Based on these statistical calculations and after rearranging the data, we found that prediction of Cormack Lehane (CL) grades can be adequately (67%-68% sensitivity) made by the ratio of Pre-E and E-VC distances (Pre-E/E-VC)  $\{0 < [\text{Pre-E/E-VC}] < 1 \approx \text{CL grade 1}; 1 < [\text{Pre-E/E-VC}] < 2 \approx \text{CL grade 2}; \text{and } 2 < [\text{Pre-E/E-VC}] < 3 \approx \text{CL grade 3}\}$ . The average time taken to complete the ultrasound examination of airway in the preoperative area was  $31.7 \pm 12.4$  seconds.

*Conclusion:* The non-invasive ultrasonographic modification of invasive Cormack Lehane classification for pre-anesthetic airway assessment can supplement the presently available non-invasive modalities of pre-anesthetic airway assessment including the Mallampati Classification.

\* Department of Anesthesiology, Wayne State University/Detroit Medical Center, Detroit, MI 48201, United States.  
**Corresponding Author:** Halim Haber, M.D., Clinical Associate Professor, Anesthesiology, Wayne State University, Box No 162, 3990 John R, Detroit, Michigan 48201, United States, Tel: 1-313-745-7233, Fax: 1-313-993-3889. E-mail: hhaber@med.wayne.edu

## Introduction

The Cormack Lehane classification is frequently used to describe the best view of the larynx seen during laryngoscopy. Although it is perhaps one of the most widely used classifications, one major drawback is that it cannot be applied for predicting difficulty in tracheal intubation in patients undergoing intubation for the first time. Direct laryngoscopy is simply too invasive of a technique to be used to assess and classify an airway in an awake patient.

Ultrasound imaging is a safe, simple, painless, and non-invasive modality through which soft tissues can be visualized and identified. However, there is limited information regarding the feasibility and potential opportunities to use ultrasound imaging for examining the upper airway<sup>1-4</sup>. Previous studies have utilized an external on-skin cricoid-level transverse scanning technique<sup>4-5</sup>, and an internal intraoral sublingual technique<sup>1-2</sup> to visualize the trachea and the esophagus, and reported difficulties associated with each technique. The major problem with the external technique is the difficulty in maintaining good probe-skin contact over an uneven and curved surface.

The purpose of this study was to compare and correlate the ultrasound view of the airway and the Cormack Lehane classification of the direct laryngoscopy.

## Methods

After institutional review board approval for the study protocol, 72 patients were enrolled in the study after obtaining the written informed consent. Only ASA class I-III patients aged 18-80 years and undergoing elective surgery requiring general anesthesia with direct laryngoscopy (Macintosh blade) and endotracheal intubation were included in the study. The patients with mouth opening too small to pass Macintosh blade 4, edentulous patients, and the patients with head and neck anatomical pathologies that might have unpredictable effect on the ultrasound assessment of the airway were excluded from the study. The patients who were not able to extend their neck >30 degrees were also excluded.

In the pre-operative holding area, the Mallampati

Classification of the pre-anesthetic airway assessment was documented as follows:

Class 1: Full visibility of tonsils, uvula and soft palate

Class 2: Visibility of hard and soft palate, upper portion of tonsils and uvula

Class 3: Soft and hard palate and base of the uvula are visible

Class 4: Only Hard Palate visible

Subsequently, the ultrasound view of the airway of all study patients was assessed by the same anesthesia resident with a high frequency linear probe (A SonoSite® MicroMaxx® ultrasound system (SonoSite INC, Bothell, WA) HFL38/13-6 MHz transducer). The patients were asked to lie down supine with active maximal head tilt-chin lift. The probe was then placed in the submandibular area in the midline. Without changing the position of the probe, the linear array of the ultrasound probe was rotated in the transverse planes from cephalad to caudal or plane "A" (a coronal plane to see the mouth opening) to plane "G" (an oblique transverse plane that bisects the epiglottis and posterior most part of vocal folds with arytenoids in one 2-dimensional view) (Fig. 1). The further rotation of the ultrasound array was ceased at the first simultaneous visualization (in the same ultrasonic frame) of the epiglottis and posterior most part of vocal folds with arytenoids (Fig. 2). The following study measurements were obtained with

*Fig. 1  
Ultrasonic Planes (Planes A-G) for the Ultrasound Assessment of the Airway*

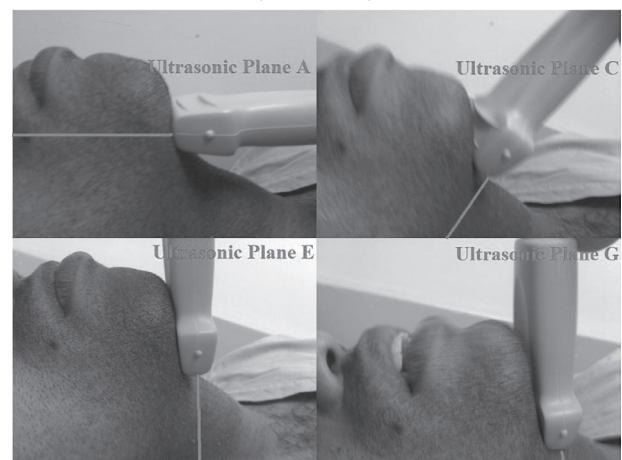
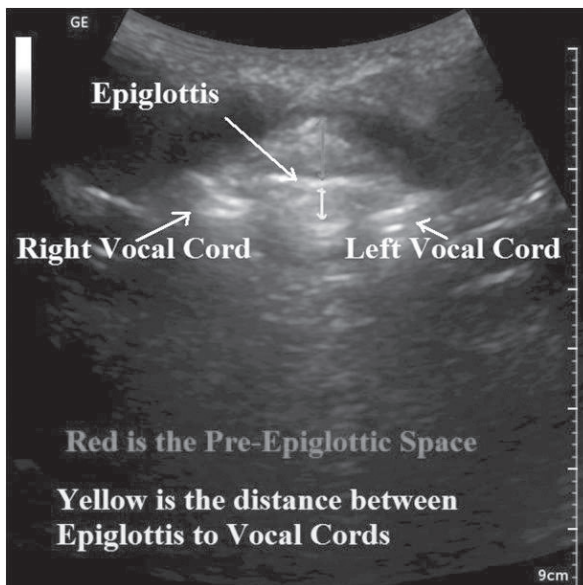


Fig. 2  
 Ultrasonic View in the Plane G for Ultrasonographic Modification of Cormack Lehane Grading



the oblique-transverse ultrasound view of the airway (Plane “G”): (a) the distance from the epiglottis to the midpoint of the distance between the vocal folds, and (b) the depth of the pre-epiglottic space (Fig. 2). The total time taken by the operator to achieve the final ultrasonic image (Plane “G”) was also recorded.

The patients were then taken to the operating room and the standard general anesthesia procedure was performed as per the discretion of the attending anesthesiologist and in accordance with good clinical practice, and per standard of care. During the intra-operative direct laryngoscopy the anesthesia providers were asked to fill out the Cormack and Lehane grading for the vocal cord view during direct laryngoscopy as per following:

Grade 1, visualization of the entire laryngeal aperture

Grade 2, visualization of parts of the laryngeal aperture or the arytenoids

Grade 3, visualization of only the epiglottis

Grade 4, visualization of only the soft palate

The Bland Altman plot with limits of agreement was drawn for the correlation of the standard of care Pre-operative Mallampati Classification with Intraoperative Cormack Lehane Grading. Subsequently, the

regression coefficients for correlating the ultrasound parameters with Cormack Lehane grading were determined and  $P < 0.05$  was considered significant. Similar to the plots described by Carvalho et al<sup>6</sup>, the logistic plots of the cumulative probability were drawn to assess the ED 50 and ED 95 for the prediction of the Cormack Lehane Grades I, II and III. Subsequently, the Receiver Operating Characteristic graphs were drawn to determine the cut-point (a whole number value of ultrasound parameter or the derivative ratio) for the most appropriate prediction of the Cormack Lehane Grades.

## Results

Out of the 72 patients enrolled in the study, first 23 enrolled patients were excluded from the final analysis as the ultrasound measurements and related technical data collection was incompletely recorded due to the initial stages of investigators’ proficiency in assessing the ultrasound imaging parameters and collection of data as the utility of the ultrasound imaging for airway assessment was very new to the research investigators. Based on the improved proficiency in appreciation of the ultrasound parameters and the collection of the complete study data in the remaining 49 patients, it was observed that there was a correlation of the distance between the epiglottis and the vocal cords (E-VC) with the Cormack Lehane Grading; correlation was strong negative with regression coefficient of  $-0.966$  (95% CI  $-1.431$  to  $-0.501$ ;  $p = 0.0001$ ). Subsequently, the correlation of the pre-epiglottic space (Pre-E) with the Cormack Lehane Grading was strong in positive direction with regression coefficient of  $0.595$  (95% CI  $0.261$  to  $0.929$ ;  $p = 0.0008$ ). Finally the ratio of Pre-E and E-VC distances with the Cormack Lehane Grading had the strongest positive correlation with regression coefficient of  $0.495$  (95% CI  $0.319$  to  $0.671$ ;  $p < 0.0001$ ). Though logistic data interpretation and analysis of our study patients (Fig. 3) suggested that ED 50 (Pre-E/E-VC values below which 50% probability for the corresponding Cormack Lehane Grade) were 0.55, 1.49 and 2.41 for Cormack Lehane Grade 1, II and III respectively and ED 95 (Pre-E/E-VC values below which 95% probability for the corresponding Cormack Lehane Grade) were 1.17, 3.33 and 4.86

Fig. 3  
Crude Data Analysis of the Study Patient Population

Cormack Lehane	Ratio of Pre-Epiglottis Space and Epiglottis-to-Vocal Cords Distance				
	Median	Range	Mean ±Standard Deviation	ED50 (Value below which 50% probability for corresponding CL Grade)	ED95 (Value below which 95% probability for corresponding CL Grade)
CL Grade 1	0.64	0.29-2.28	0.89 ±0.61	0.55	1.17
CL Grade 2	1.52	0.49-3.32	1.65 ±0.81	1.49	3.33
CL Grade 3	2.24	1.28-4.37	2.54 ±0.98	2.41	4.86
CL Grade 4	No data yet	No data yet	No data yet	No data yet	No data yet

for Cormack Lehane Grade 1, II and III respectively, after rearranging the data (Fig. 4-5) for simplification, we found that prediction of Cormack Lehane (CL) grades can be adequately (67%-68% sensitivity) made by the ratio of Pre-E and E-VC distances (Pre-E/E-VC) { $0 < [Pre-E/E-VC] < 1 \approx$  CL grade 1;  $1 < [Pre-E/E-VC] < 2 \approx$  CL grade 2; and  $2 < [Pre-E/E-VC] < 3 \approx$  CL grade 3} (Fig. 6). The Bland-Altman scatter plot for pre-operative Mallampati Classification and intra-operative Cormack Lehane Grading (Fig. 7) showed large and wide limits of agreement (-1.66 to + 1.70) but these differences between the two grading systems

were statistically insignificant. The average time taken to complete the ultrasound examination of airway was  $31.7 \pm 12.4$  seconds.

**Discussion**

The presently available non-invasive modality of airway assessment primarily include (but not limited to) Mallampati Classification, thyromental distance assessment, and atlanto-occipital (neck) extension; and in the pre-operative holding areas, the anesthesiologists usually come to a conclusion of a predicted difficult

Fig. 4  
Probability and Cumulative Probability Graphs of the Cormack Lehane Classification in correlation with Ultrasound Assessment of the Airway

Ratio of Distance	Cumulative Probability of Cormack Lehane1	Ratio of Distance	Cumulative Probability of Cormack Lehane2	Ratio of Distance	Cumulative Probability of Cormack Lehane3
<1	0.67	<1	0.26	<1	0
<2	0.94	<2	0.68	<2	0.25
<3	1	<3	0.95	<3	0.67
<4	0	<4	1	<4	0.83
<5	0	<5	0	<5	1

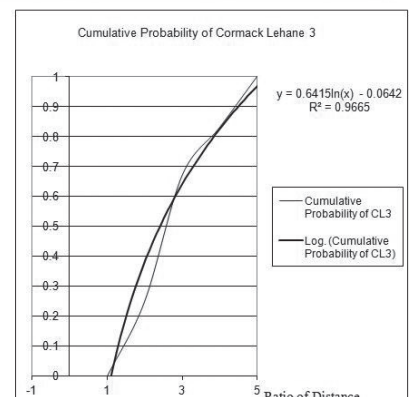
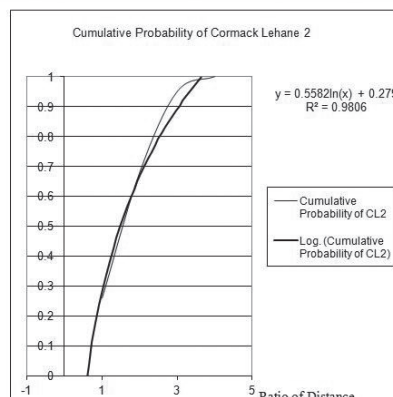


Fig. 5  
Incidence Graph of the Cormack Lehane Classification and its correlation with Ultrasound Assessment of the Airway

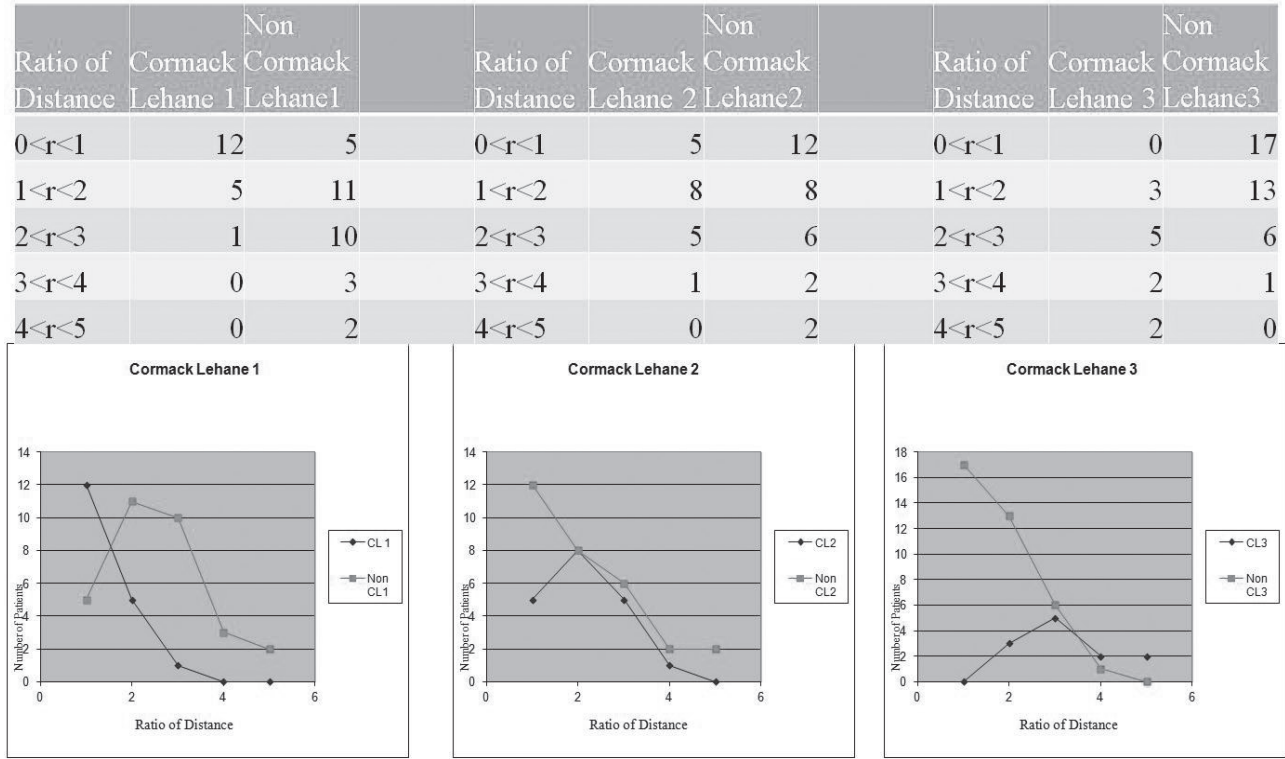


Fig. 6  
Receiver Operating Characteristic Graphs for the Development of the Ultrasonographic Modification of Cormack Lehane Grading

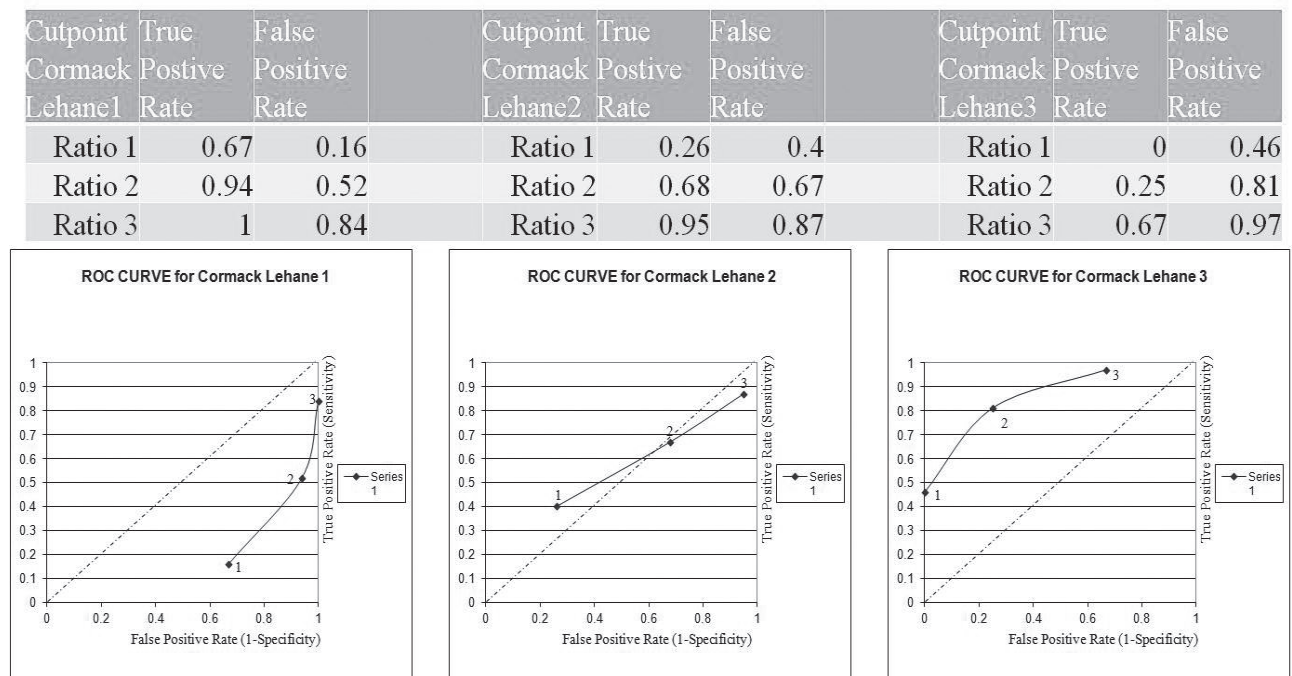
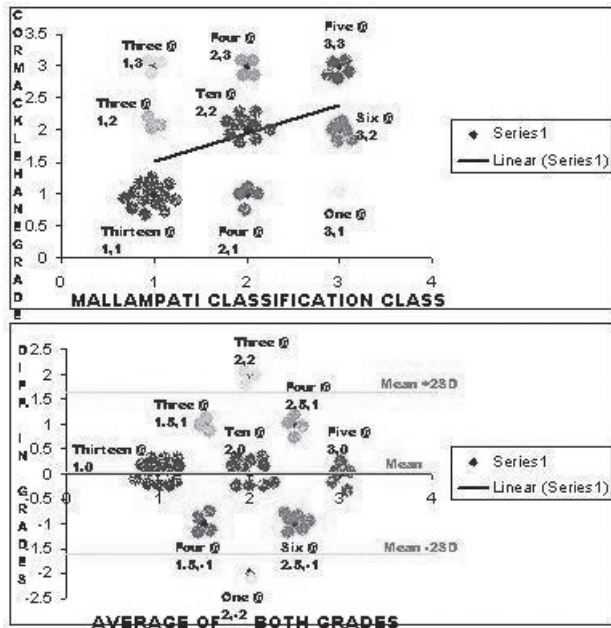


Fig. 7

Bland Altman Plot for Correlation of Preoperative Mallampati Classification and Intraoperative Cormack Lehane Grading



or easy airway based on their combined assessment of the above mentioned predictors with other external observations like mouth opening and head and neck pathologies (LEMON Score)<sup>7-9</sup>. However, it is not always feasible to do a complete airway examination in urgent/emergent clinical scenarios in agitated, non-cooperative or unconscious patients. Moreover, as observed in our analysis, the intra-operative laryngoscopy grade (Cormack Lehane Classification) may not always correlate adequately well with the pre-operative predictors of airway assessment. Hence there is always a need of non-invasive but more accurate airway assessment of the airway in the pre-operative holding area as researchers have documented questionable feasibility of the invasive transnasal flexible fiberoptic airway assessment in the pre-operative area<sup>10-11</sup>. Additionally, the time constraints of operating room complexes may limit the possibility of testing for any new modalities of airway assessment in the pre-operative holding areas unless the innovative applications for assessing the airway is not time consuming for both the patients and the anesthesia care providers.

The present study demonstrates that Cormack Lehane Classification can be appropriately assessed by the ultrasound examination of the neck that takes

approximately 30 seconds to reach a conclusion as regards to the ultrasonographic modification grade of Cormack Lehane Classification. This fast and quick airway assessment can be a good supplementary tool in the busy anesthesiologists' armamentarium wherein the anesthesia care teams can rest assured that before transferring the patients to the operating room they have insightful visuals of the patients' airways that was obtained non-invasively and without much delays in the daily routines of anesthesia caregiving.

We devised the oblique G plane (Fig. 1) to document the ultrasonographic modification grade of Cormack Lehane Classification that was quick to achieve and easy to calculate the ratio of the distances (Pre-E/E-VC). Even though the sensitivity was only 67%-68% (possibly due to the small number of patients), the rapidity of this ultrasound application in the airway assessment may pave a way for future pre-anesthetic airway assessment wherein the intra-operative Cormack Lehane Classification can be routinely predicted based on the ratio of the pre-epiglottic space depth and the epiglottis-to-vocal-cords distance. We devised this ratio for the classification because it is our understanding that the larger pre-epiglottic space as well as smaller E-VC distance will have correlation with increasing difficulty in the airway instrumentation (laryngoscopy and intubation) in terms of the Cormack Lehane Classification grading. Moreover if the pre-epiglottic space is very large in a patient but the ratio is small because of larger E-VC distance in the patient, the predicted airway in the patient will be easy and intraoperative Cormack Lehane grade in the patient will be low; the only concern for airway management in the patient will be that the laryngoscopy to achieve the low grade of Cormack Lehane classification will be tedious secondary to larger force required to lift the large epiglottis as reflected by the deep pre-epiglottic space.

We acknowledge the limitations of our classification. The number of the patients was small. We did not have any Cormack Lehane grade IV patients in our study. Based on the assessment of the Receiver Operating Characteristic curves (Fig. 6) for each Cormack Lehane Grades, it will be more prudent to say that as the Cormack Lehane Classification is a continuum of the four grades (only three grades were

observed and studied in our study patient population), the extremes of the Cormack Lehane grade (grade I and III) will be better assessed and predicted by the ratio of the distances (Pre-E/E-VC) than the Cormack Lehane grade II. Even though we did not have any Cormack Lehane grade IV patients, it may be easily theorized by our results and analysis that in Cormack Lehane grade IV patients, the pre-epiglottic space will be very large with very high probability of the large epiglottis obscuring the ultrasonographic visualization of the non-phonating vocal cords in the ultrasonic plane "G", and the calculation of the ratio of the distances (Pre-E/E-VC) may be impossible in the indirectly predicted (prediction by exclusion) Cormack Lehane grade IV patients. For a better neck skin surface contact, the concave curve high frequency transducer has yet not been developed and this may delay the routine use of ultrasound in the airway assessment as standard of care.

## Conclusion

The ultrasonographic modification of Cormack-Lehane Classification was developed with 67%-68% sensitivity as per the ratio of the distances [Pre-E/E-VC]:

$$0 < [\text{Pre-E/E-VC}] < 1 \approx \text{CL grade 1}$$

$$1 < [\text{Pre-E/E-VC}] < 2 \approx \text{CL grade 2}$$

$$2 < [\text{Pre-E/E-VC}] < 3 \approx \text{CL grade 3}$$

The non-invasive ultrasonographic modification of invasive Cormack Lehane classification for airway assessment can supplement the presently available non-invasive modalities of pre-anesthetic airway assessment including the Mallampati Classification.

## References

1. TSUI BC, HUI CM: Sublingual airway ultrasound imaging. *Can J Anaesth*; 2008, 55:790-1.
2. TSUI BC, HUI CM: Challenges in sublingual airway ultrasound interpretation. *Can J Anaesth*; 2009, 56:393-4.
3. SINGH M, CHIN KJ, CHAN VW, WONG DT, PRASAD GA, YU E: Use of sonography for airway assessment: an observational study. *J Ultrasound Med*; 2010, 29:79-85.
4. LAKHAL K, DELPLACE X, COTTIER JP, TRANQUART F, SAUVAGNAC X, MERCIER C, FUSCIARDI J, LAFFON M: The feasibility of ultrasound to assess subglottic diameter. *Anesth Analg*; 2007, 104:611-4.
5. ADHIKARI S, ZEGER W, SCHMIER C, CRUM T, CRAVEN A, FRROKAJ I, PANG H, SHOSTROM V: Pilot study to determine the utility of point-of-care ultrasound in the assessment of difficult laryngoscopy. *Acad Emerg Med*; 2011, 18:754-8.
6. CARVALHO B, DURBIN M, DROVER DR, COHEN SE, GINOSAR Y, RILEY ET: The ED50 and ED95 of intrathecal isobaric bupivacaine with opioids for cesarean delivery. *Anesthesiology*; 2005, 103:606-12.
7. SOYUNCU S, EKEN C, CETE Y, BEKTAS F, AKCIMEN M: Determination of difficult intubation in the ED. *Am J Emerg Med*; 2009, 27:905-10.
8. REED MJ, DUNN MJ, MCKEOWN DW: Can an airway assessment score predict difficulty at intubation in the emergency department? *Emerg Med J*; 2005, 22:99-102.
9. REED MJ, RENNIE LM, DUNN MJ, GRAY AJ, ROBERTSON CE, MCKEOWN DW: Is the 'LEMON' method an easily applied emergency airway assessment tool? *Eur J Emerg Med*; 2004, 11:154-7.
10. ROSENBLATT W, IANUS AI, SUKHUPRAGARN W, FICKENSCHER A, SASAKI C: Preoperative endoscopic airway examination (PEAE) provides superior airway information and may reduce the use of unnecessary awake intubation. *Anesth Analg*; 2011, 112:602-7.
11. AKÇA O, LENHARDT R, HEINE MF: Can transnasal flexible fiberoptic laryngoscopy contribute to airway management decisions? *Anesth Analg*; 2011, 112:519-20.